

DIAGNOSIS OF HELMINTH INFECTIONS

Helminths are cosmopolitan and play a significant role in the morbidity and mortality of people in many parts of the world, especially among the poorer classes in third world countries. Most prevalent are the intestinal helminths and infection with these helminths are most often diagnosed by finding and identifying eggs and/or juvenile nematodes when examining fecal specimens. Either fresh or preserved specimens may be used for diagnosing an infection. Although the utilization of certain specific products, procedures, and techniques for collecting, preserving, and examining fecal specimens may be given emphasis, most of the material that relates to parasites applies regardless of the collection method, specific product, or procedure employed.

Identifying an egg found but not readily recognized often presents a problem for the laboratory worker and may require looking in several reference sources before identification can be made. Size, shape, structure, and stage can each impact on identification. The relative size of some eggs seen in a fecal specimen is shown in Plate 1. If an appropriate reference source is not readily available, identification may take several days or sometimes longer.

The Structure of Helminth Eggs

Plate 2 shows drawings of representative eggs and their structures from each group, trematodes, cestodes, and nematodes. These structures are also used in the Key to Helminth Eggs Found in Feces and most are defined in the glossary. The eggs drawn in the plate are representative of those with more simple structure (e.g. hookworm) and others with more complicated structure (e.g., *Hymenolepis diminuta*), and some just beginning development (*Ascaris lumbricoides*) and other with complete embryos (*Schistosoma mansoni*). All of the structures identified in the plate may not be evident in eggs found in a fecal preparation. Usually, in specimens examined or preserved immediately after passage there are sufficient features for the observer to make an identification. In some cases, closely related species have eggs that appear identical (e.g., *Taenia solium* and *T. saginata*). Since the eggs of these two species cannot be readily differentiated, characteristics of the gravid proglottid or scolex are used to identify the species present. Other members of the family Taeniidae produce similar eggs (members of the genera *Echinococcus* and *Multiceps*) but man is not infected by the adult stage and therefore eggs are not found in human feces.

INTRODUCTION TO THE KEY TO HELMINTH EGGS FOUND IN FECES

In developing the key, the author has relied on many reference sources for basic information. Those eggs that are most commonly seen in fecal specimens have been included. Some species, such as *Capillaria philippinensis* and *Ternidens deminutus*, seen only in limited geographic areas, have been included because of the ease of travel from those areas. Other species, such as *Dicrocoelium dendriticum* and the free-living *Heterodera* sp., seen as spurious infections, have been included also. Others that are rarely seen, for example *Capillaria hepatica* and *Schistosoma mekongi*, have been omitted.

It was necessary to rely on various literature sources to arrive at the outer extremes of the sizes of eggs used in the Key. Although some of these have been confirmed using specimens available, confirming all size ranges was not possible. In a few instances, sizes of eggs consistently exceeded reports in the literature and the size range was changed to reflect these differences. The author would welcome comments based on actual measurements of eggs from properly identified species that vary from those given in the Key.

In addition to those species of helminths infecting man, eggs of mites, insects, helminths of animals, and free-living helminths may be accidentally ingested, move through the gastrointestinal tract, and pass with the feces. The presence of such unusual eggs in fecal specimens adds to difficulty in making accurate and positive identifications. Eggs in spurious infections are usually present only for 1 or at the most 3 days and would not be found in subsequent fecal specimens, which further substantiates the importance of collecting several specimens on alternate days from each patient being examined. Obviously, it is impractical to include in the Key all eggs that might be found in fecal specimens.

There are some places in the Key where one may have some difficulty in making a decision. For example, in deciding if a small operculate egg, 35 μm or less, has a miracidium with symmetrical or asymmetrical organs, particularly cephalic (cytolytic) glands may prove problematic. Anyone, even an experienced parasitologist, may have some trouble with this decision. It will be necessary to use high magnification (1000x), and even turn the egg around to make the determination.

The most recent treatment is the same for many of the trematodes. Those producing small operculate eggs, e.g., *Clonorchis sinensis*, *Opisthorchis viverrini*, infecting the liver and *Heterophyes heterophyes* infecting the intestine can be treated similarly. The pathologic effects on the host are different for different species, so a specific diagnosis should be made when possible.

Regardless of some difficulties, the Key does provide a practical, effective approach to the identification of helminth eggs that are found in fecal specimens but not readily recognized, particularly when supported by photomicrographs and drawings. Those who have used the Helminth Egg Key have found it helpful.

KEY TO HELMINTH EGGS FOUND IN FECES

1. a. Egg with operculum, sometimes inconspicuous.....2
- b. Egg without operculum.....13
2. a. Small egg 35 μm or less; containing a larva when passed.....3
- b. Larger egg, greater than 35 μm ; with or without developed larva.....7
3. a. Eggs with opercular shoulders; when passed, organs of larva are not obviously symmetrical but are asymmetrical.....4
- b. Eggs without opercular shoulders; when passed, organs of larva are, particular cephalic glands, are obviously symmetrical.....6
4. a. Egg ovoidal (light-bulb-shaped), with pronounced shoulders: narrow, raised operculum; abopercular end with a button-hook projection, sometimes incomplete; 27 to 35 x 12 to 20 μm ; in feces or duodenal drainage, = *Clonorchis sinensis*
- b. Egg with pronounced shoulders; abopercular end with or without raised papillae or knob.....5
5. a. Egg ovoidal (light-bulb-shaped); with a slightly raised, relatively broad operculum; abopercular end with or without prominent papilla; 23 to 33 x 12 to 20 μm ; from feces or duodenal drainage. = *Opisthorchis viverrini*
- b. Egg more slender and tapering from center to both ends; papillae on abopercular end, if present, small; average size 30 x 20 μm ; in feces or duodenal drainage. = *Opisthorchis felineus*
6. a. Egg without distinct shoulders; broadest below the middle; slight or no thickening at abopercular end; 24 to 28 x 115 to 17 μm ; in feces. = *Metagonimus yokogawai*
- b. Egg without distinct shoulders; broadest at middle; slight or no thickening at abopercular end; 26 to 30 x 15 to 17 μm ; in feces. = *Heterophyes heterophyes*
7. a. Egg very large; over 130 μm in length.....8
- b. Egg less than 125 μm in length.....10
8. a. Egg oval in shape.....9
- b. Egg rhomboid, widest in the middle and tapering toward both ends; 150 to 170 x 60 to 70 μm ; in feces. = *Gastrodiscoides hominis*
9. a. Egg 130 to 145 x 60 to 75 μm ; with yoke granules evenly distributed throughout yoke cells; in feces.¹ = *Fasciolopsis buski*
- b. Egg 130 to 155 x 65 to 90 μm ; with yoke granules concentrated around nuclei of yoke cells; in feces or from duodenal drainage.¹ = *Fasciola hepatica*

¹ It is often impossible to distinguish between the latter two species by the examination of the eggs. Collecting bile fluid from the opening of the common bile duct may be necessary to confirm or eliminate *Fasciola hepatica*. A few cases of human infection with *F. gigantica* have been reported. The eggs are extremely large, 150 to 196 x 90 to 100 μm and should be distinguishable from *F. hepatica* or *Fasciolopsis buski*.

10. a. Egg less than 50 μm and containing a larva when passed; with a thick shell usually more rounded on one side; 35 to 45 x 22 to 30 μm ; in feces or from duodenal drainage; usually seen as a spurious infection. = *Dicrocoelium dendriticum*
- b. Egg over 50 μm and not containing a larva when passed.....11
11. a. Egg with flattened operculum and pronounced shoulders; abopercular end of shell thickened; 75 to 120 x 45 to 65 μm ; in sputum; or in feces in 1/3 to 1/2 of the cases. = *Paragonimus westermani*
- b. Egg without shoulders, operculum rounded and often indistinct.....12
12. a. Egg relatively thin-shelled; oval in shape with a narrow operculum, sometimes difficult to see; 85 to 115 x 45 to 65 μm ; in feces. = *Echinostoma ilocanum*
- b. Egg relatively thick-shelled; broadly barrel-shaped with a relatively broad operculum often difficult to see; abopercular end of shell with a button-like thickening slightly off center; 55 to 75 x 38 to 55 μm ; in feces. = *Diphyllbothrium latum*
13. a. Egg contains a ciliated larva; has a conspicuous spine or minute knob, the knob often difficult to see.....14
- b. Egg does not have a ciliated larva; without a spine or minute knob.....17
14. a. Egg with a conspicuous spine.....15
- b. Egg broadly oval, with a minute knob on one side near base of egg; often with a loose coating covering the shell; 70 to 108 x 55 to 80 μm ; in feces. = *Schistosoma japonicum*
15. a. Egg with a terminal spine.....16
- b. Egg large, elongated with a lateral spine; 110 to 180 x 45 to 75 μm ; in feces, rarely urine. = *Schistosoma mansoni*
16. a. Egg with terminal spine; 140 to 220 x 50 to 90 μm ; tapering slightly toward both ends and thickest in the center; in feces.² = *Schistosoma intercalatum*
- b. Egg with terminal spine; 100 to 170 x 50 to 80 μm ; narrowly ovoidal; usually in urine, rarely in feces.² = *Schistosoma haematobium*

² *S. intercalatum* infection in man has been reported from seven countries in Africa. It has a larger size range than *S. haematobium* (140 to 220 μm in length). Since the size ranges overlap, it may be necessary to use means other than size to differentiate between the two species. In South Africa, other species with terminal spines, *S. matthei* (180 to 232 μm in length) and *S. bovis* (180 to 232 μm in length), are rarely seen in human feces. Human infection with these latter species is accidental and some reports may reflect spurious infections. The eggs of *S. rodhaini*, a species infecting rodents, having a subterminal spine, and a rounded knob at the opposite end, have been recovered from the feces and from tissues of humans in Africa.

17. a. Egg fully embryonated; containing an embryo without cilia and with three pair of hooklets, sometimes difficult to see.....18
- b. Egg either fully embryonated or not fully embryonated but never with hooklets.....21
18. a. Egg with a single, thick, dark, radially pitted shell; spherical, 30 to 60 μm ; subspherical, 30 to 40 x 20 to 30; in feces = *Taenia sp.*
- b. Egg shell moderately thin without radial pitting; embryophore encasing hexacanth embryo separated from shell by a relatively large space.....19
19. a. Egg single; embryophore with polar thickenings.....20
- b. Eggs usually in packets of 10 to 25; single eggs without thickenings or filaments on the embryophore; shell thin and nearly transparent; spherical, 30 to 60 μm ; in feces. = *Dipylidium caninum*
20. a. Egg oval with thin shell composed of two layers; embryophore with polar thickenings from which filaments extend into space beneath inner shell; diameter 30 to 60 μm ; in feces.³ = *Hymenolepis nana*
- b. Egg round to slightly oval; outer shell thicker and dark; embryophore occupies about one-third of space within shell, with polar thickenings but without polar filaments; diameter 65 to 85 μm ; in feces = *Hymenolepis diminuta*
21. a. Egg with a thick, dark shell.....22
- b. Egg with a clear, transparent shell.....26
22. a. Egg barrel-shaped; with Mucoïd plug at each pole; with smooth shell.....23
- b. Egg round to oval, without Mucoïd plugs at the poles; shell covered with a rough mammillated coating.....25
23. a. Egg small with flattened sides and blunt ends; shell with radial striations, 36 to 45 x 19 to 22 μm ; in feces. = *Capillaria philippinensis*
- b. Egg tapering to both poles; shell without striations.....24
24. a. Egg tapering from center toward both poles; 50 to 65 x 22 to 30 μm ; in feces. = *Trichuris trichiura*
- b. Egg larger, 70 to 88 x 25 to 30 μm , often slightly flattened at middle and tapering to both poles; in feces. = *Trichuris vulpis*
25. a. Egg round to broadly oval; 45 to 75 x 35 to 50 μm ; in feces. (normal fertile egg) = *Ascaris lumbricoides*
- b. Egg elongate, oval or rhomboidal; no organized embryo present; 88 to 95 x 40 to 45 μm ; in feces.⁴ = *Ascaris (unfertilized)*

³ The shells of *Hymenolepis* spp. eggs have two parts; an outer dark covering that may be lost in fixed specimens exposing an inner, almost clear shell wall.

⁴ Either fertile or infertile eggs may lose their cortex in the specimen. In such cases, the very thick clear shell helps differentiate *Ascaris* eggs from those of similar size.

26. a. Egg shell very thick; often seen in older preserved specimens or those where fixation has been delayed.....27
- b. Egg shell thin.....28
27. a. Egg contents not segmented beyond four cell stage; 43 to 68 x 33 to 48 µm; in feces. = *Ascaris* (decorticated)
- b. Egg with larval stage inside; 48 to 52 x 32 to 36 µm; in feces. = *Physaloptera caucasica*
28. a. Egg flattened on one side.....29
- b. Egg not flattened on one side.....30
29. a. Egg contains a partially developed, rhabditoid juvenile; 50 to 65 x 20 to 30 µm; relatively rare in feces; or with a fully developed juvenile, found in folds of anus. = *Enterobius vermicularis*
- b. Egg bean-shaped with air spaces at poles; larva developed to morula stage; 80 to 120 x 20 to 45 µm; in feces. = *Heterodera* sp.
30. a. Egg with both poles rounded.....31
- b. Egg with one pole more pointed than the other; embryo usually developed to the morula stage; 70 to 100 x 24 to 45 µm; in feces. = *Trichostrongylus* sp.
31. a. Egg developed to the four to eight cell stage; 56 to 70 x 35 to 50 µm; in feces. = *Hookworm* sp.
- b. Egg with embryo developed beyond eight cell stage.....32
32. a. Egg with embryo from 16 cells to rhabditoid juvenile stage; 56 to 70 x 35 to 50 µm; in feces.⁵ = *Hookworm* sp.
- b. Egg with embryo developed to eight cells or greater but not to juvenile stage; 75 to 85 x 46 to 55 µm; in feces.⁶ = *Ternidens deminutus*

⁵ Hookworm eggs in human feces may represent either *Ancylostoma* sp. or *Necator americanus*. Differentiation must be made from adult or Filariform juvenile stage. The Filariform stage is obtained for identification by culturing the eggs or juvenile worms (Melvin and Brooke, 1982; Ash and Orihel, 1987). When hookworm eggs are delayed in moving through the intestine, they may develop to the juvenile stage. Some juvenile worms may emerge in feces before it is passed so, in addition to eggs, occasionally juvenile nematodes of hookworms are seen in the fecal specimen. The juvenile stages of *Strongyloides stercoralis* also may be present in fecal specimens where hookworm eggs are present. In such cases, the juveniles must be positively identified.

⁶ Hookworm eggs are differentiated from *Ternidens deminutus* eggs only on the basis of size.

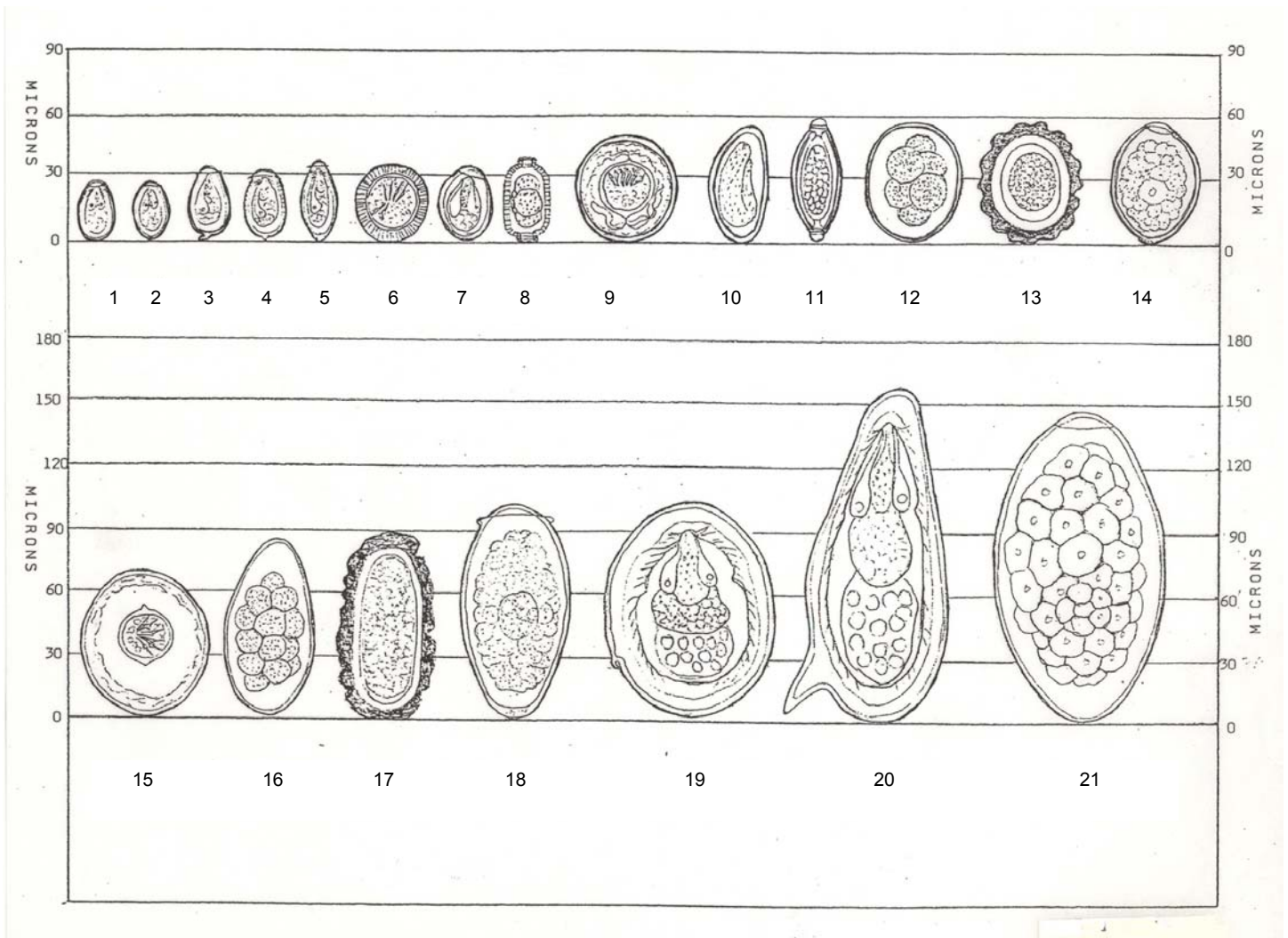
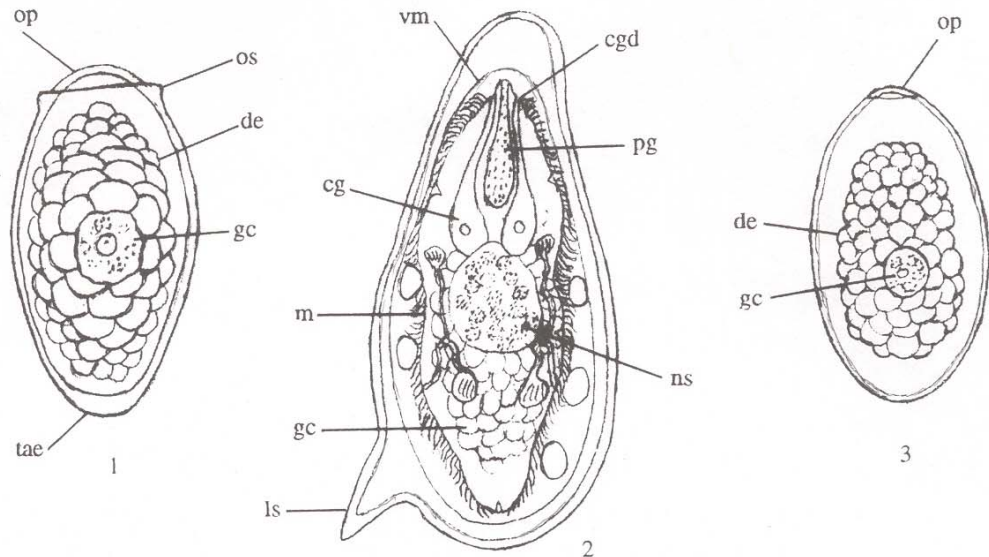


Plate 1: Diagrams of trematode eggs. The identification of each trematode egg is given along with its average size, length, or diameter, in μm .

Number	Name	Length (μm)
1	<i>Metagonimus yokogawai</i>	26
2	<i>Heterophyes heterophyes</i>	28
3	<i>Clonorchis sinensis</i>	31
4	<i>Opisthorchis viverrini</i>	28
5	<i>Opisthorchis filenius</i>	30
6	<i>Taenia</i> spp.	35
7	<i>Dicrocoelium dendriticum</i>	40
8	<i>Capillaria philippinensis</i>	40
9	<i>Hymenolepis nana</i>	45
10	<i>Enterobius vermicularis</i>	57
11	<i>Trichuris trichiura</i>	60
12	Hookworm spp.	63
13	<i>Ascaris lumbricoides</i> (fert)	57
14	<i>Diphylobothrium latum</i>	65
15	<i>Hymenolepis diminuta</i>	75
16	<i>Trichostrongylus</i> sp.	85
17	<i>Ascaris lumbricoides</i> (unfert)	91
18	<i>Paragonimus westermani</i>	97
19	<i>Schistosoma japonicum</i>	89
20	<i>Schistosoma mansoni</i>	145
21	<i>Fasciola hepatica</i>	140

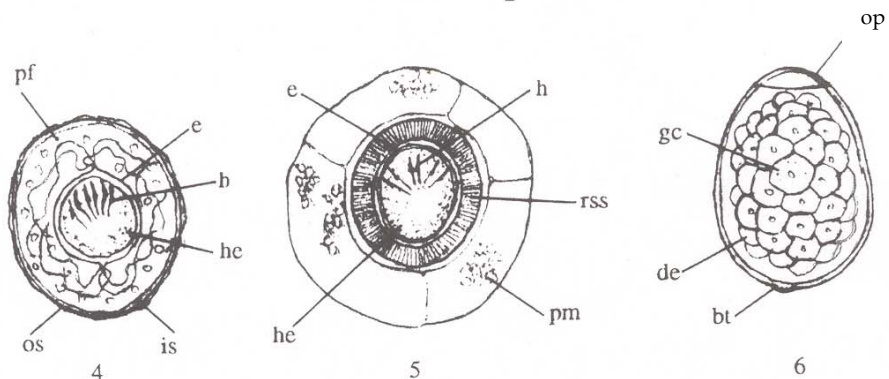
Trematodes

1. *Paragonimus westermani*
2. *Schistosoma mansoni*
3. *Echinostoma ilocanum*



Cestodes

4. *Hymenolepis nana*
5. *Taenia sp.*
6. *Diphyllobothrium latum*



Nematodes

7. Hookworm
8. *Trichuris trichiura*
9. *Ascaris lumbricoides*

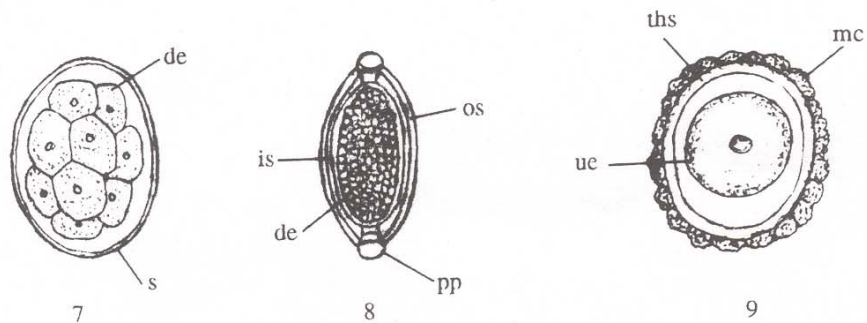


Plate 2: The structures seen in eggs representing each Helminth group

Abbreviations

bt: button-like thickening
 cg: cephalic gland
 cgd: cephalic gland duct
 de: developing embryo
 e: embryophore
 gc: germ cell
 h: hooklet
 he: hexacanth embryo
 is: inner shell

ls: lateral spine
 m: miracidium
 mc: mammillated coat (cortex)
 ns: nervous system
 op: operculum
 ops: opercular shoulders
 os: outer shell
 pf: polar filaments
 pg: primitive gut

pm: primary membrane
 pp: polar plugs
 rss: radially striated shell
 s: shell
 tae: thickened abopercular end
 ths: thick hyaline shell
 ue: unsegmented embryo
 vm: vitelline membrane