


EMERGENCY DERMATOLOGY 1.0

JIM GILLEN MD FACEP



WHY DID YOU GO INTO
EMERGENCY
MEDICINE?

AHMET DONMEZER

COWBOY

JILL VOLK

COWGIRL

KANT SHAH

THE LADIES

CHARLOTTE AND JOSH

PRIVATE TIME

JASON WILSON

PRESIDENT OF THE
UNITED STATES

WHY EMERGENCY MEDICINE?

MAKE A DIFFERENCE

ABCDE

- A → ASYMMETRIC
- B → BORDER
- C → COLOR
- D → DIAMETER (>> PENCIL ERASER)
- E → EVOLVING

Goals and Objectives

- Goals
- Understand the presentations of various dermatologic diseases seen in the ED
- Differentiate benign and life threatening dermatologic diseases
- Objectives
- Recognize and identify the common skin lesions presenting to the ED
- Learn the treatment of common and life threatening dermatologic diseases

Macules, Papules, Nodules and Vesico-Bullous Lesions

- Greater than 3,000 Skin Diseases
- ~5% of ED visits in the USA
- **History**
 - **a. Age**
 - **b. Duration**
 - **c. Associated symptoms**
 - **i. Itching**
 - **ii. Fever**

History (continued)

- **iii. Pain**
- **d. Travel/Location**
- **e. Sick Contacts**
- **f. Past Medical History**
- **g. Medications – new**
- **h. Menstrual history**
- **i. Sexual history**
- **j. Vaccinations**

Nodule

- A palpable solid lesion > 5 or 10 mm in diameter, that may or may NOT be elevated
- Small lipomas, epidermoid/sebaceous cysts, erythemanodosum, lymphomas, fibromas, various neoplasms
- Large Nodules → >>20 mm are called tumors, whether benign or malignant

Macule

- Circumscribed area of change without elevation
- A flat discolored spot of varied size and shape
- PATCH → macule of > 10 mm
- Examples are freckles, flat moles, port-wine stains, tattoos and the rashes of
- Rickettsial infections, rubella and rubeola

Papule

- Solid elevated lesion usually < 10 mm in diameter
- PLAQUE: a group of confluent papules
- Diseases starting with Papules
- Warts, psoriasis, syphilis, lichen planus, drug eruptions, pigmented moles, seborrhea and actinic keratoses
- Some phases of acne and epitheliomas

Vesicle

- A circumscribed elevated lesion < 5 mm in diameter that contains serous fluid
- BULLA aka Blister → are just vesicles > 5 mm
- Primarily caused by primary irritant or allergic contact dermatitis
- Trauma, sunburn, insect bites, viral infections such as hsv and zoster, drug eruptions, pemphigus, dermatitis herpetiformis, pemiphigoid

Pustule

- A superficial, elevated lesion containing pus
- Pustules may result from infection OR the “seropurulent evolution of a vesicle or bullae”
- Impetigo, acne, furuncles, abscesses, chancroid, deep fungal infections, hidradenitis suppurativa, kerion and psoriasis of the palms and soles

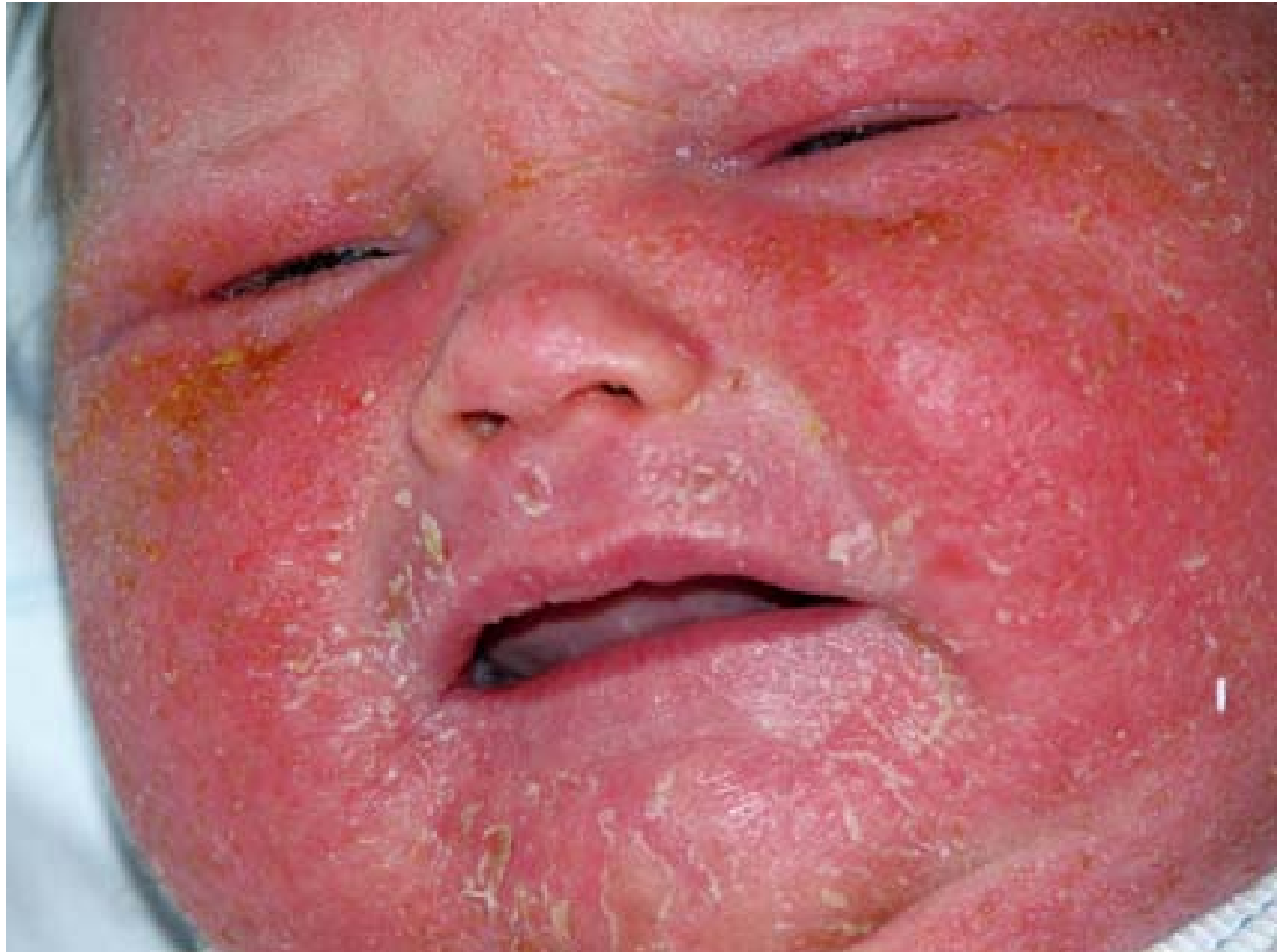Wheal

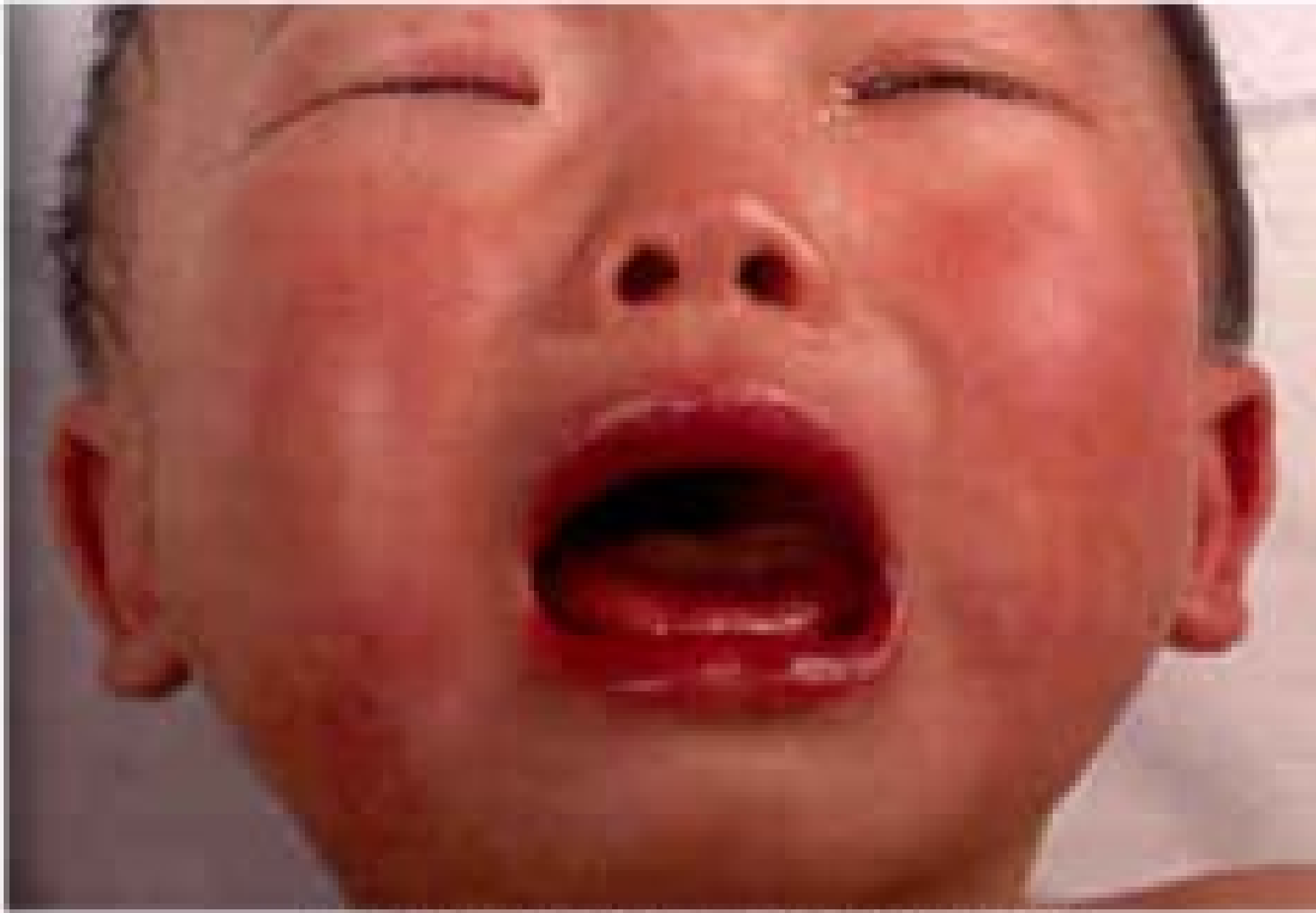- “A transient elevated lesion caused by local edema”
- Wheal are a common allergic reaction
- Drug eruptions, insect bites or stings, sensitivity to
- cold, heat, pressure or sunlight

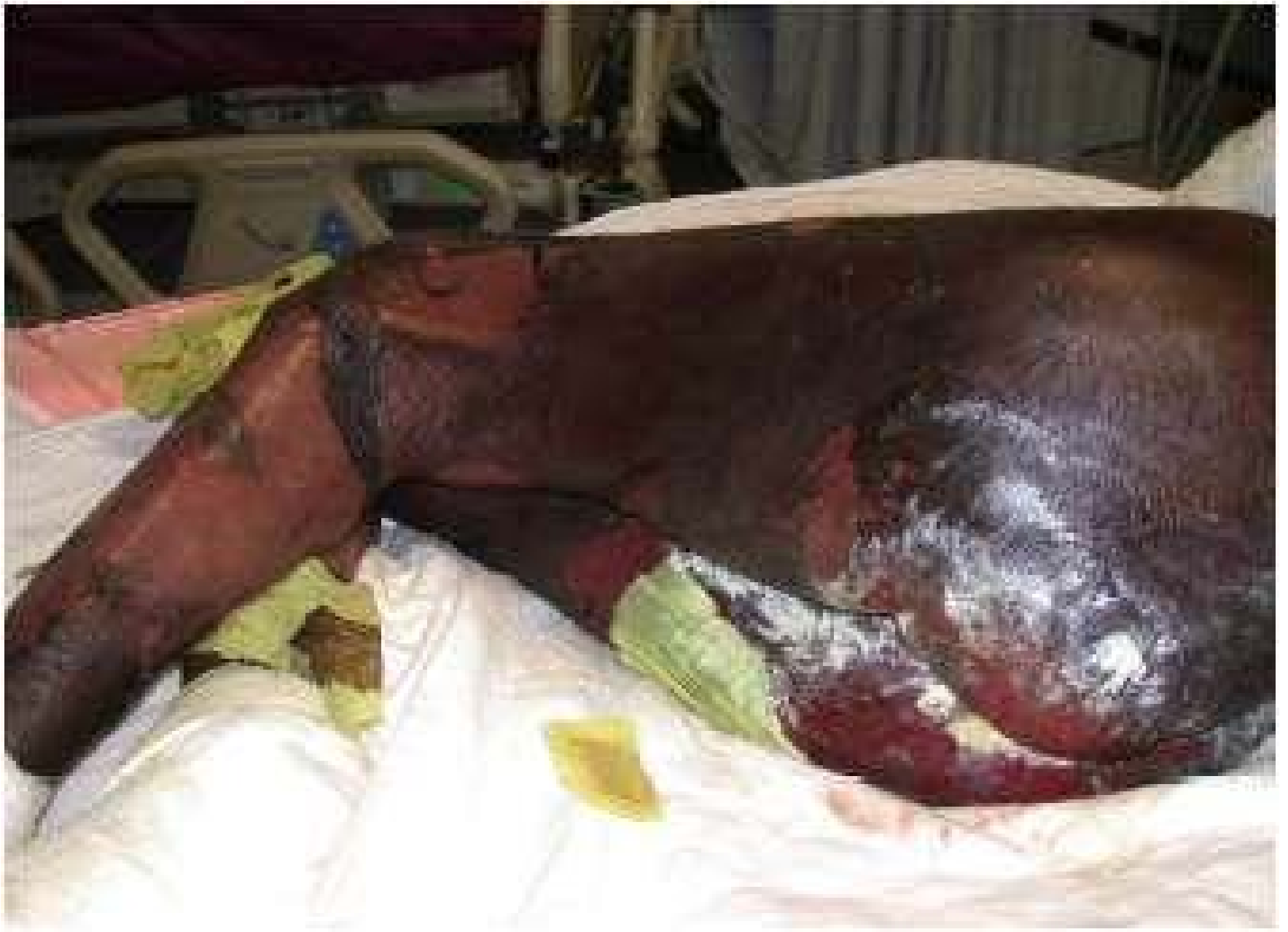Telangectasias

- “Dilatation of superficial blood vessels”
- May be seen in certain systemic diseases
- Ataxia Telangectasia and Scleroderma
- Topical fluorinated corticosteroids
- Often unknown etiology or old age

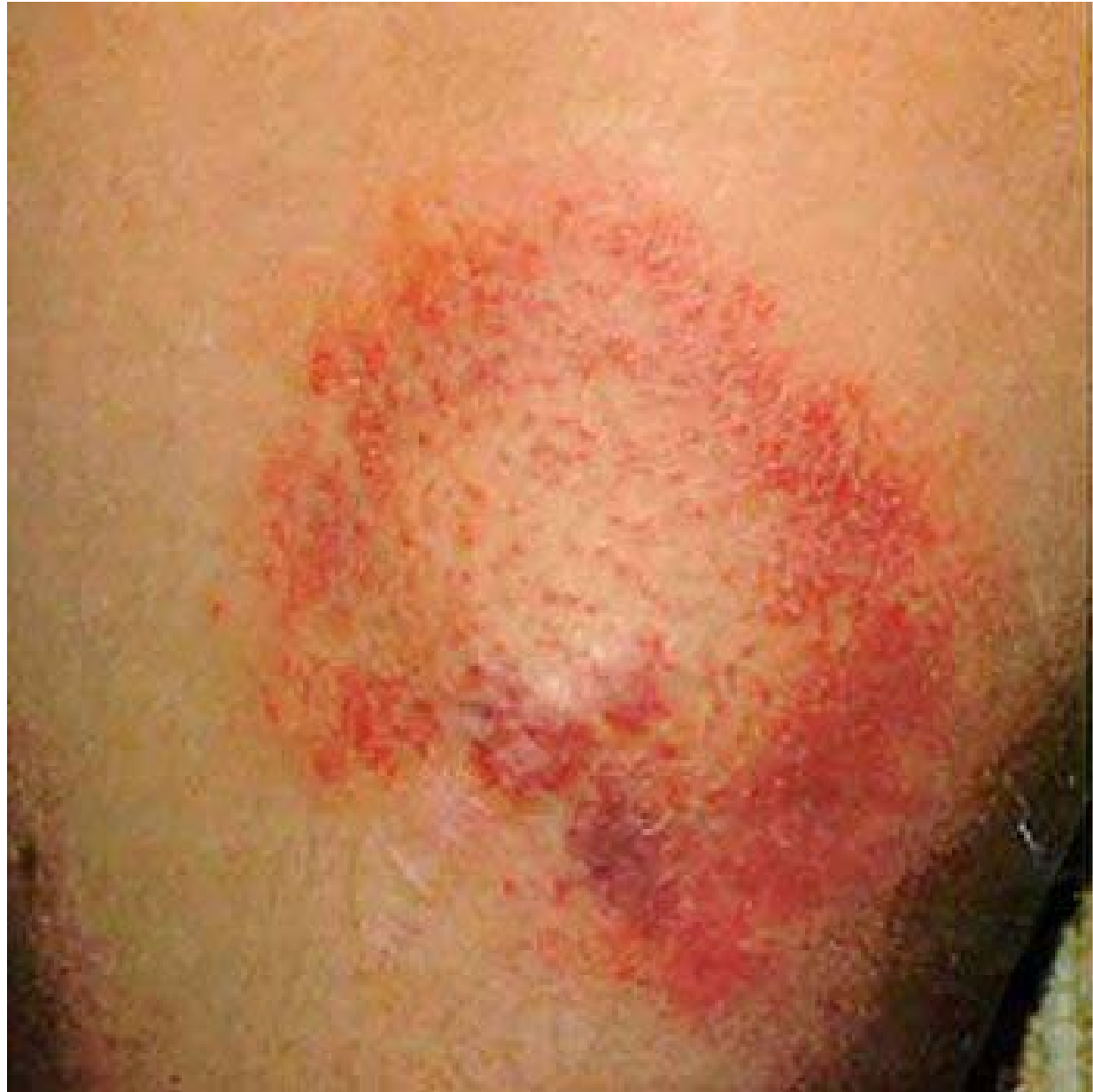JEOPARDY











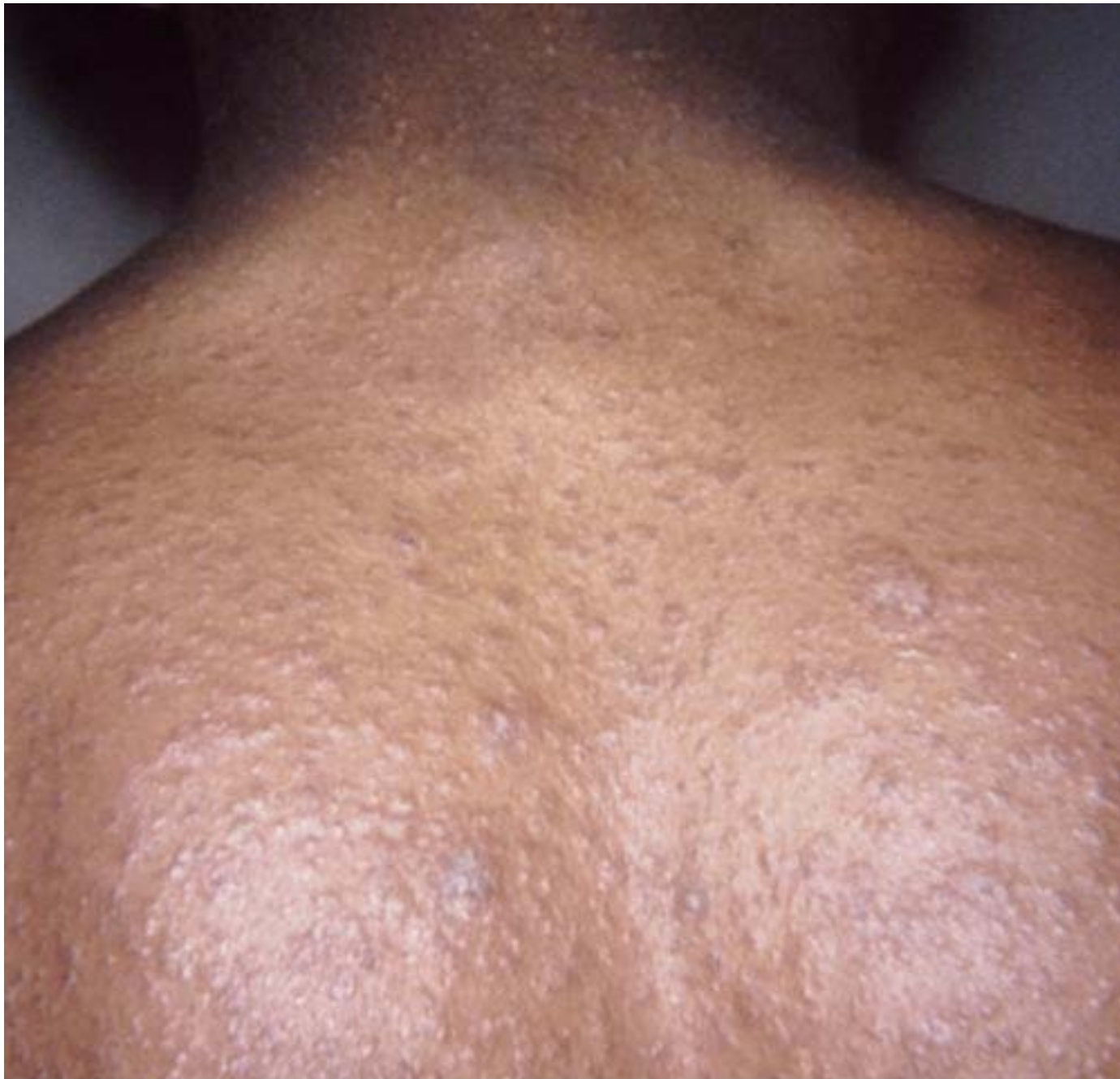
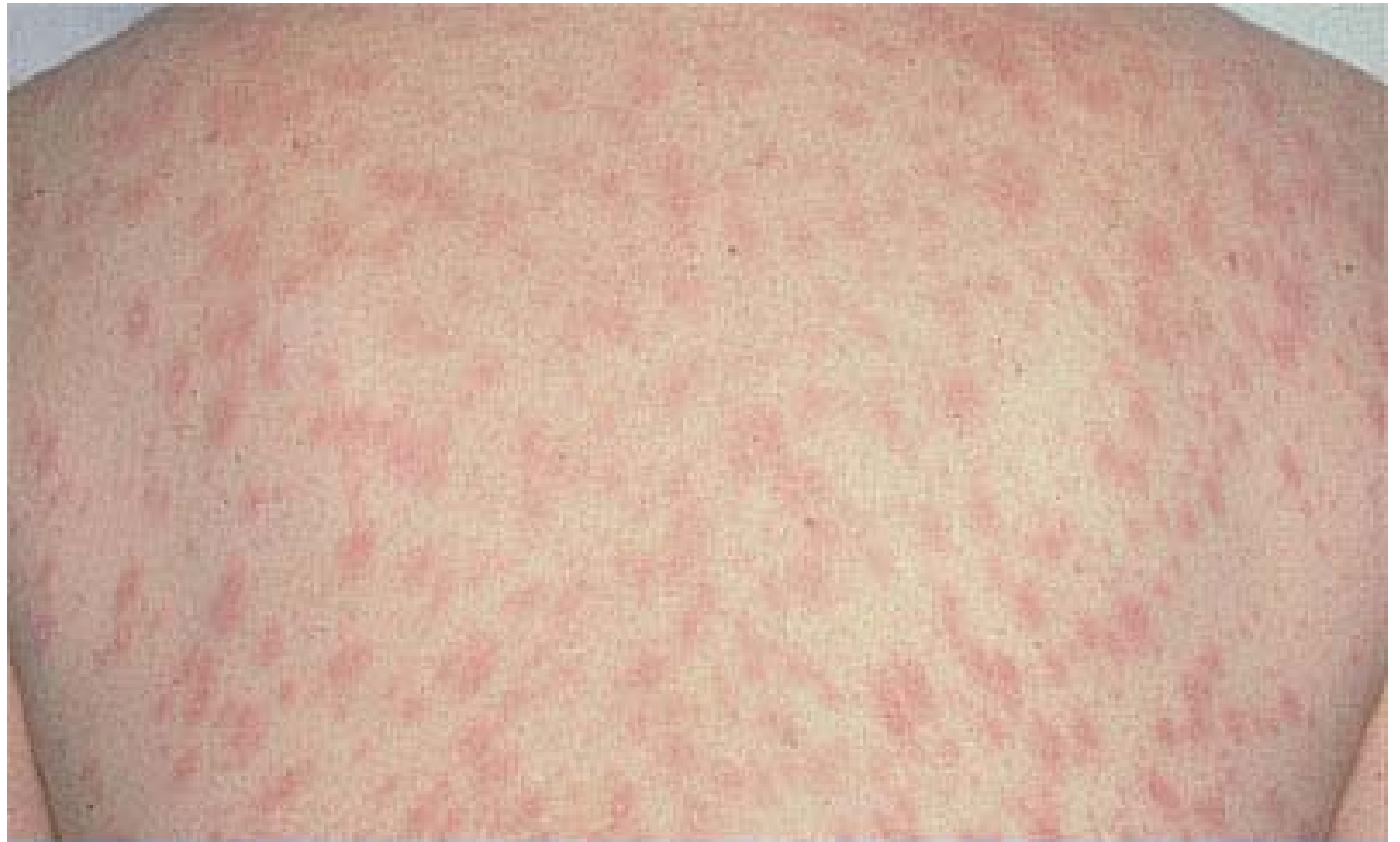
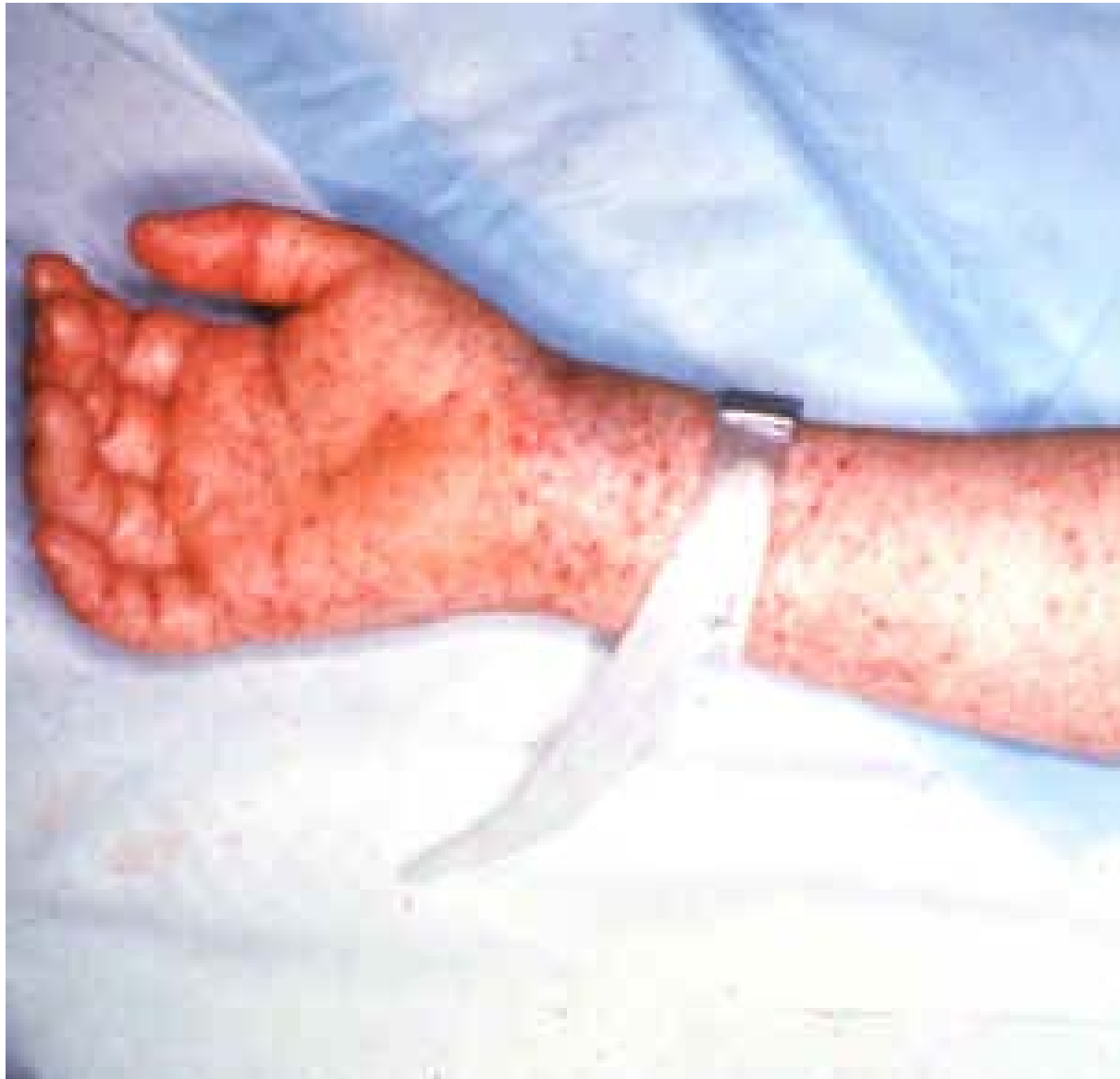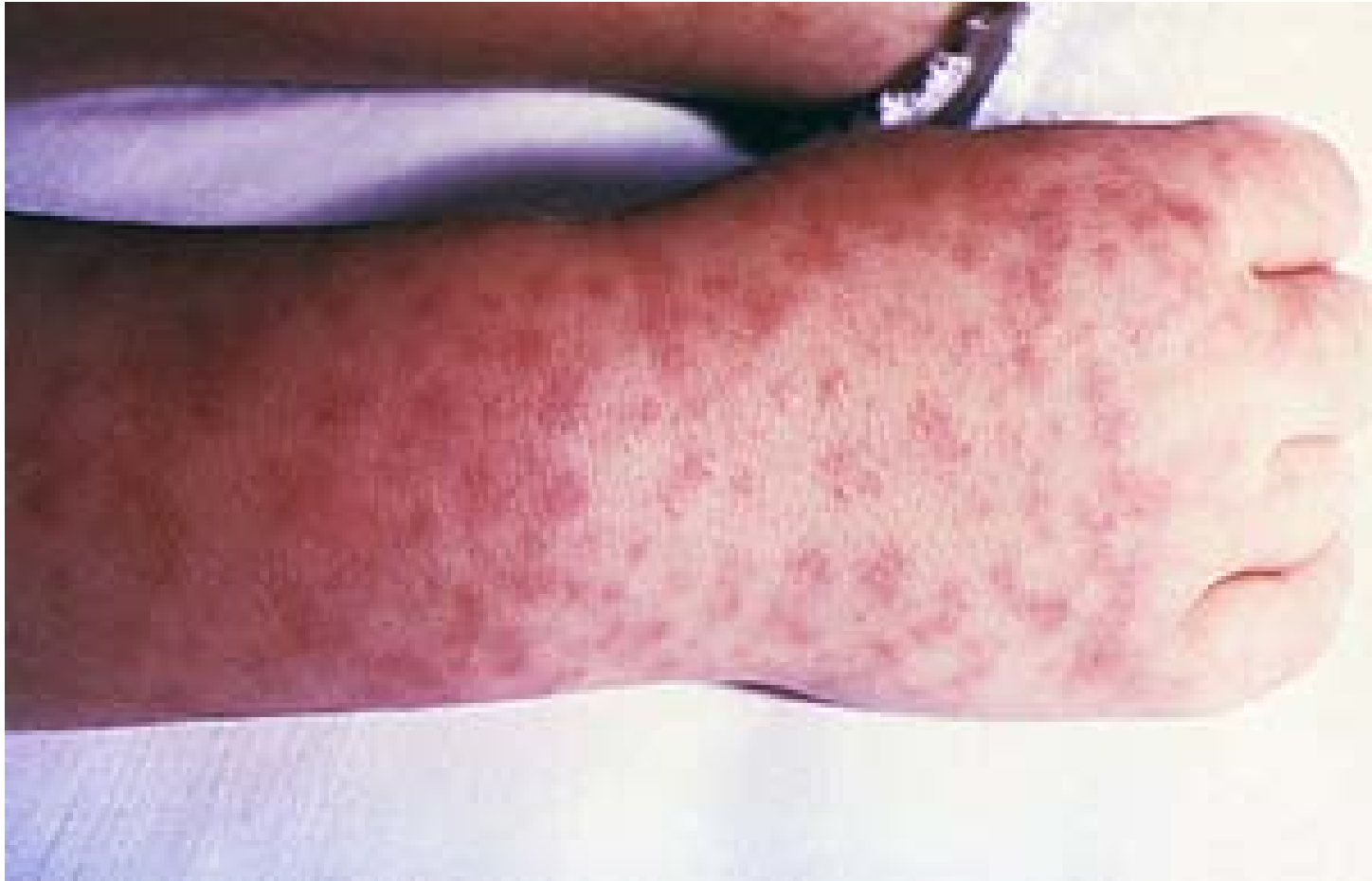Photo Courtesy of CDC - Richard Deitrick



© Mayo Foundation for Medical Education and Research. All rights reserved.



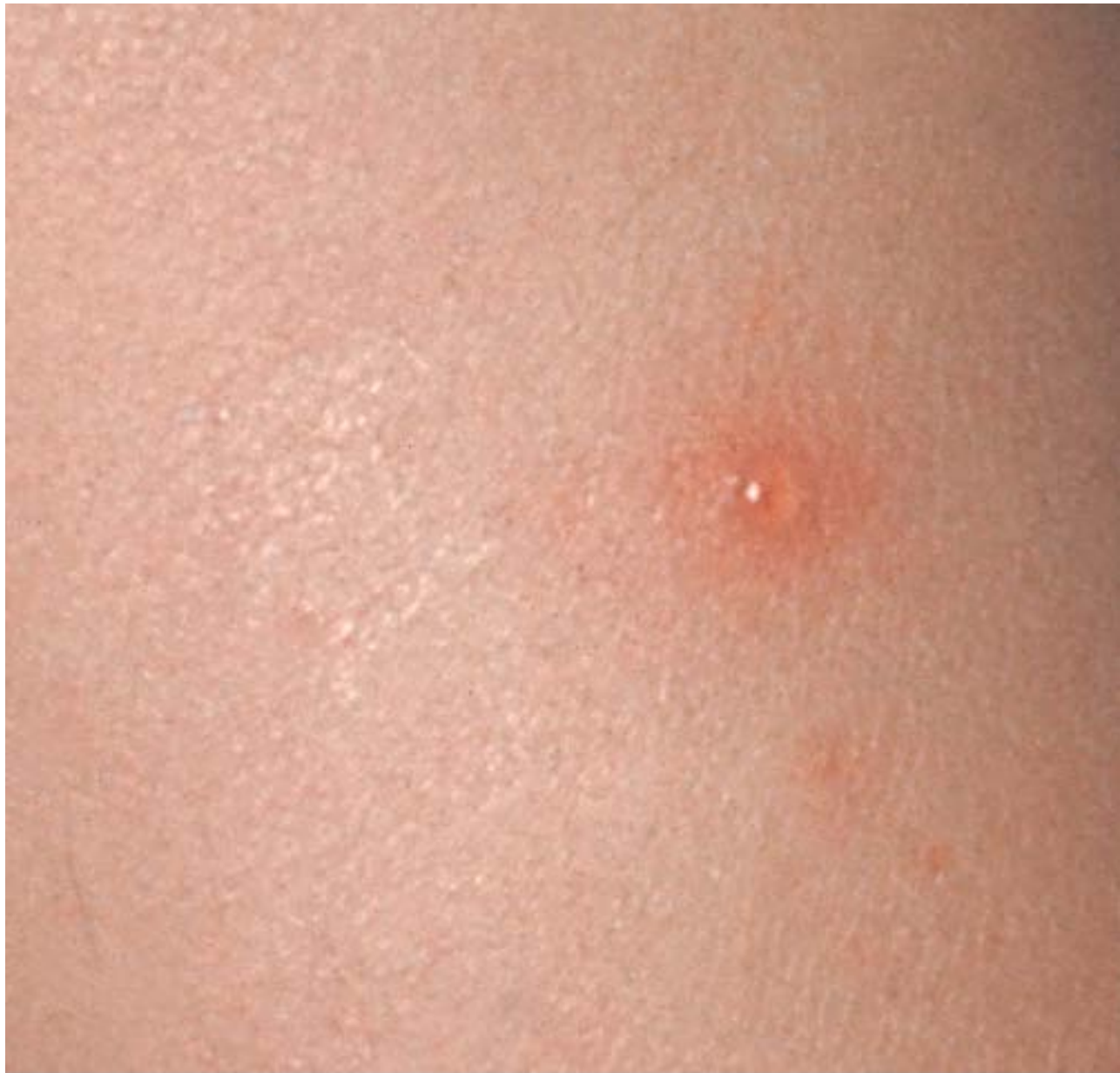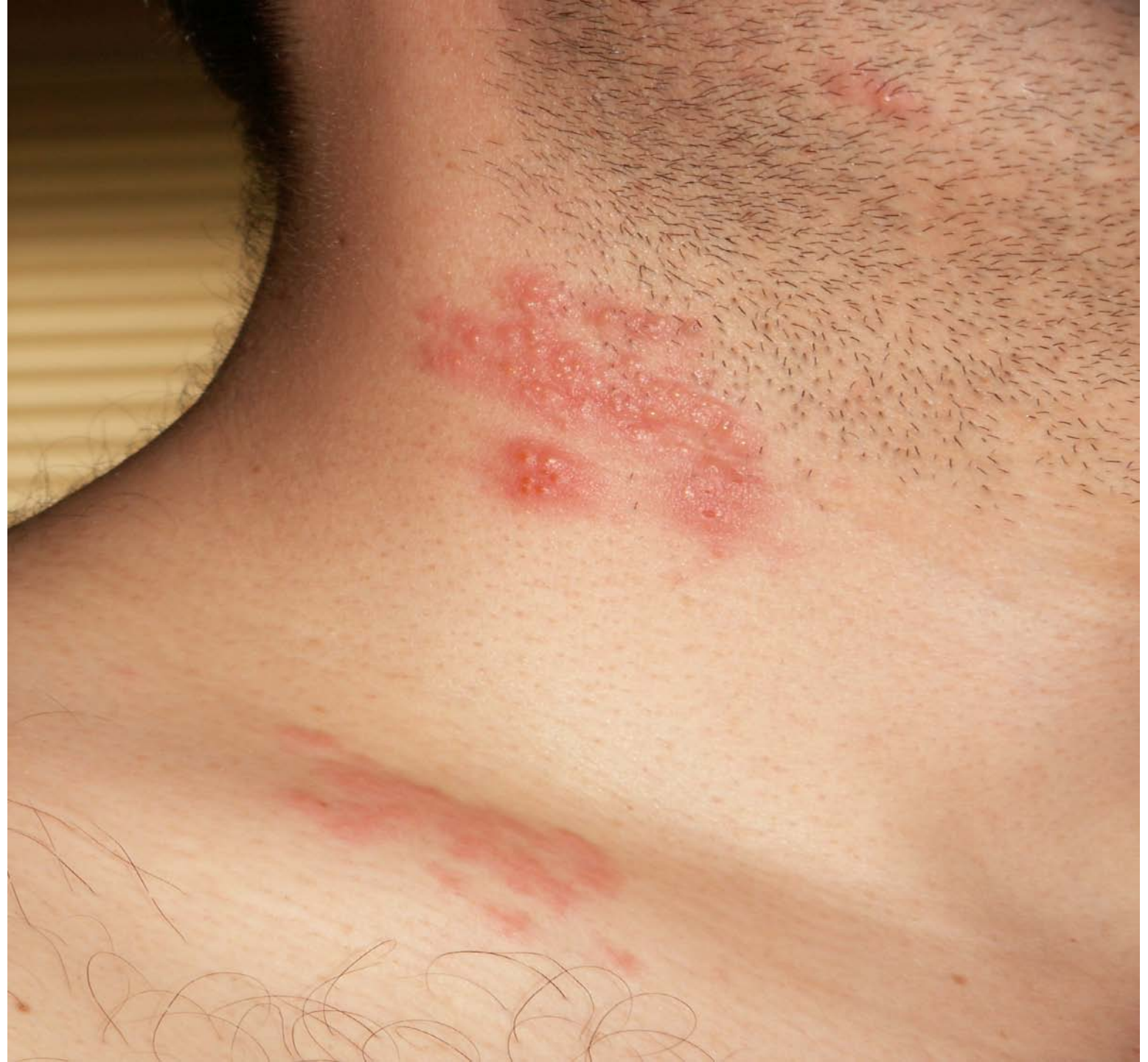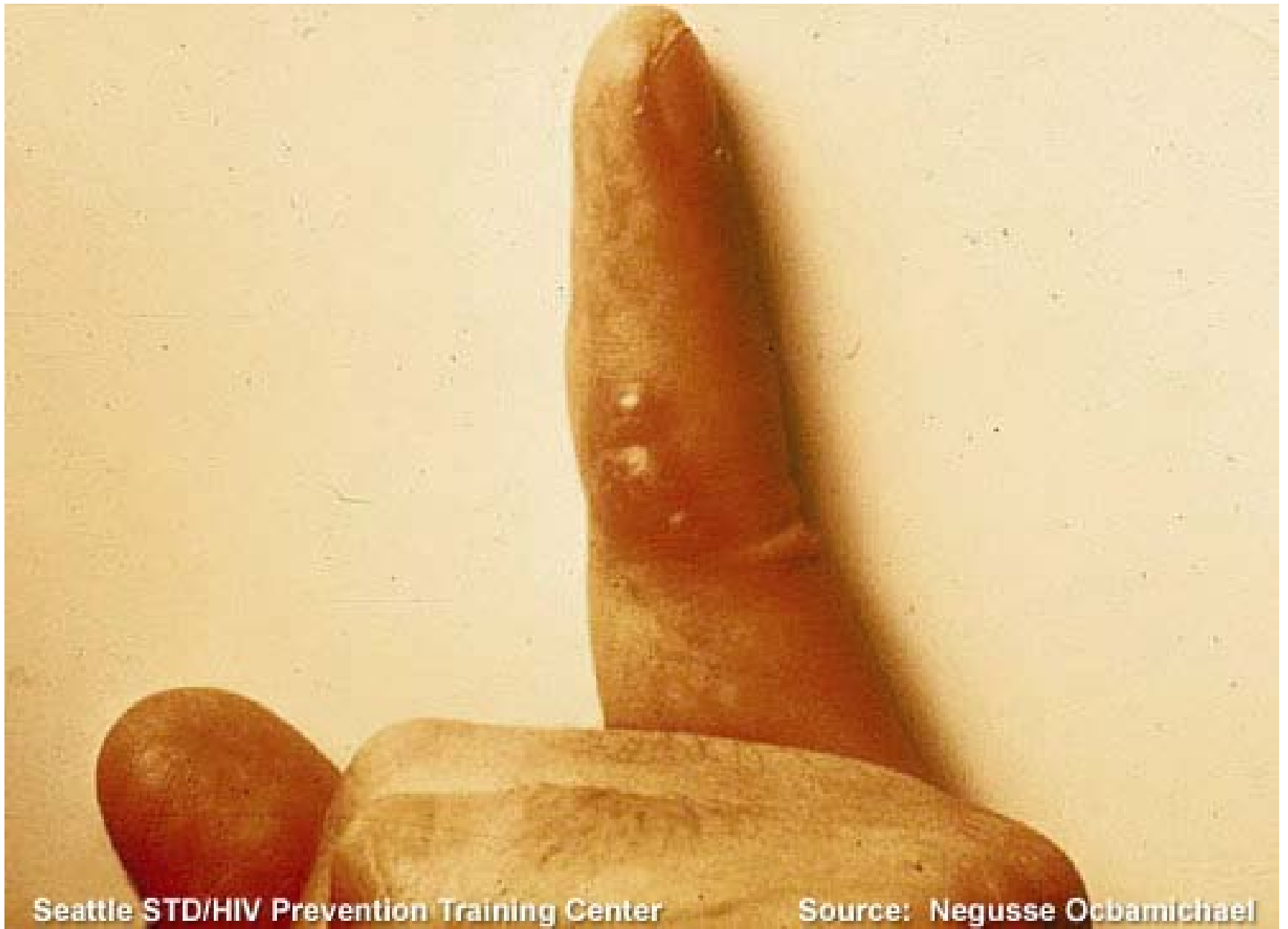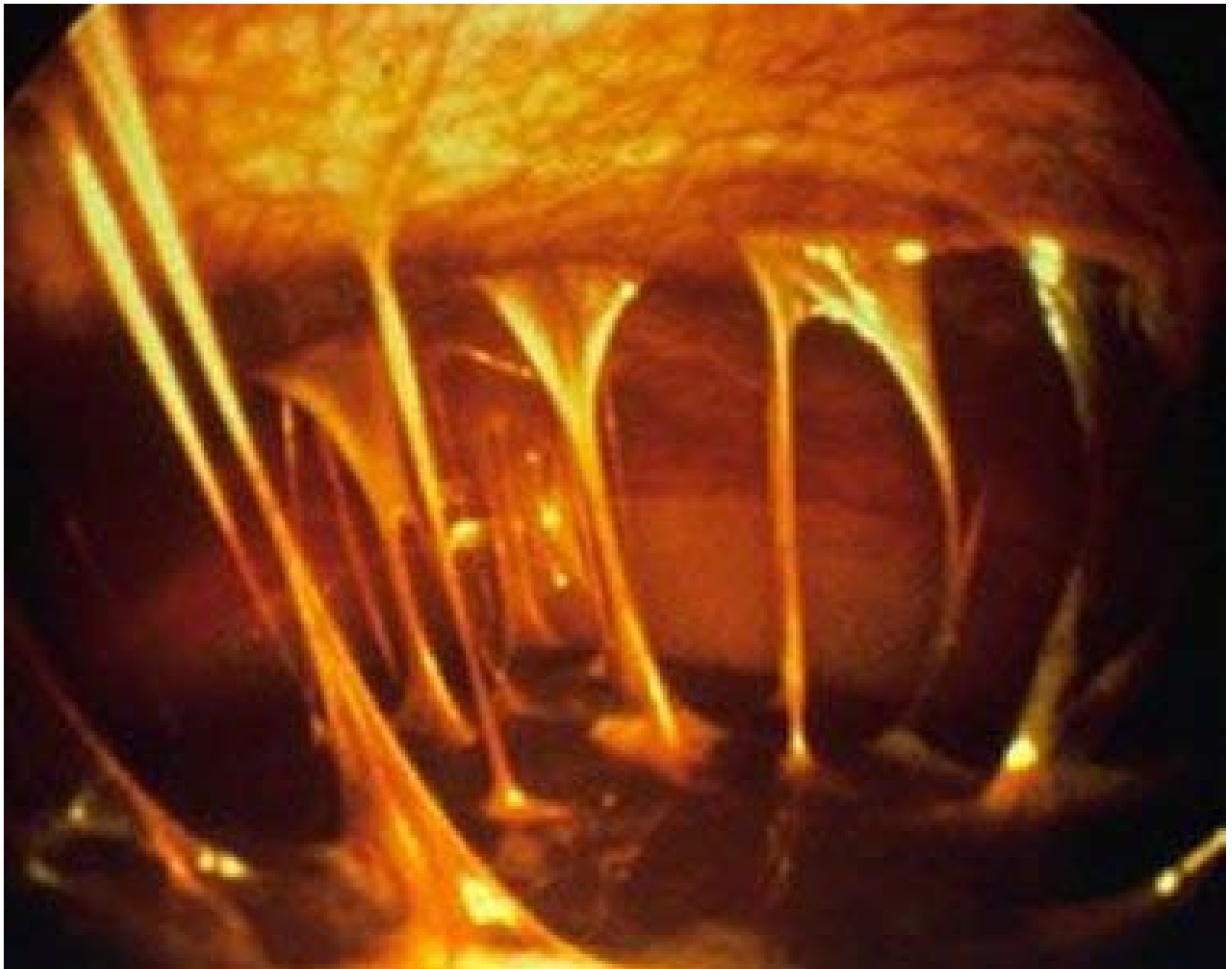




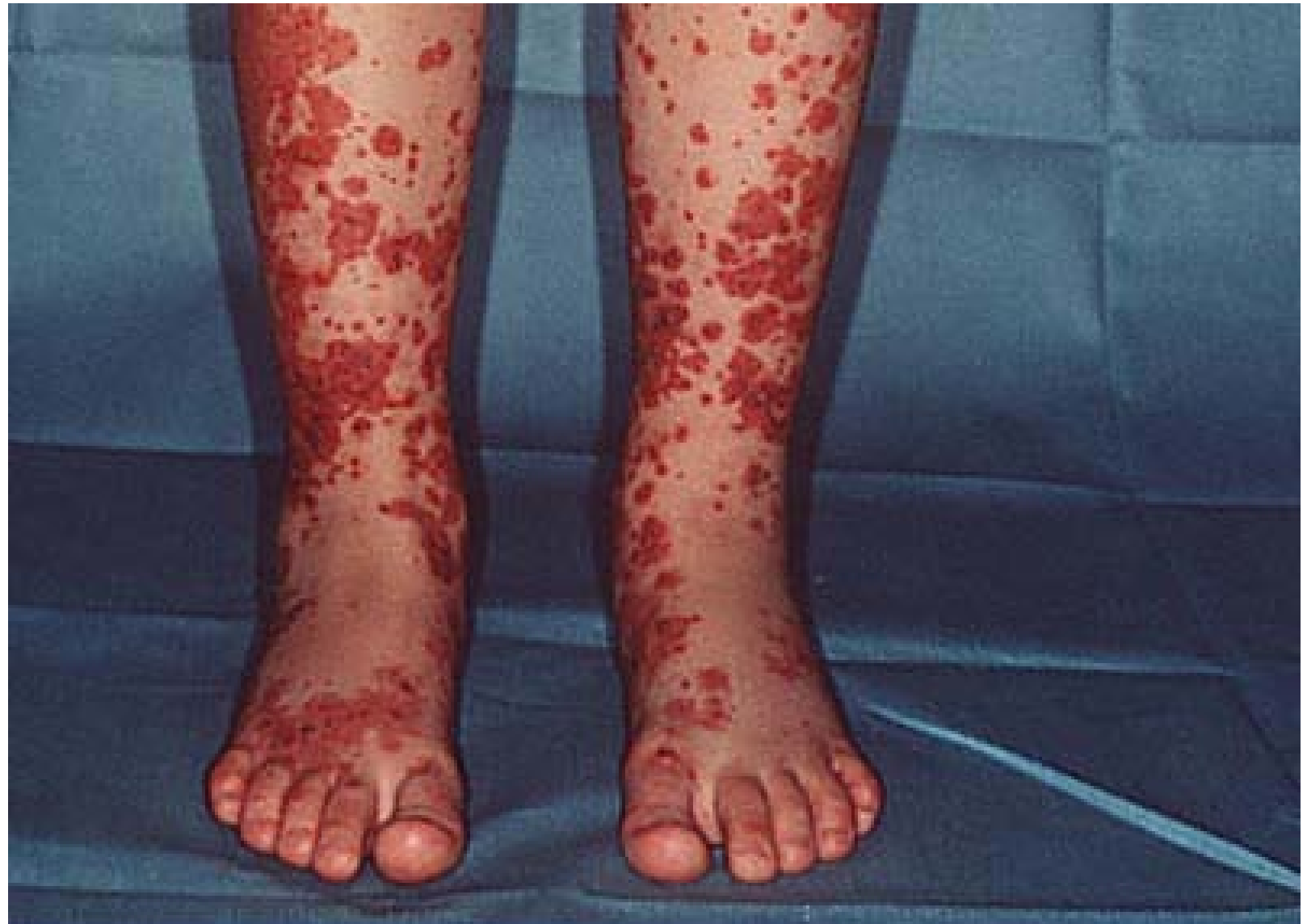Photo Courtesy of CDC - Dr. Heinz F. Eichenwald

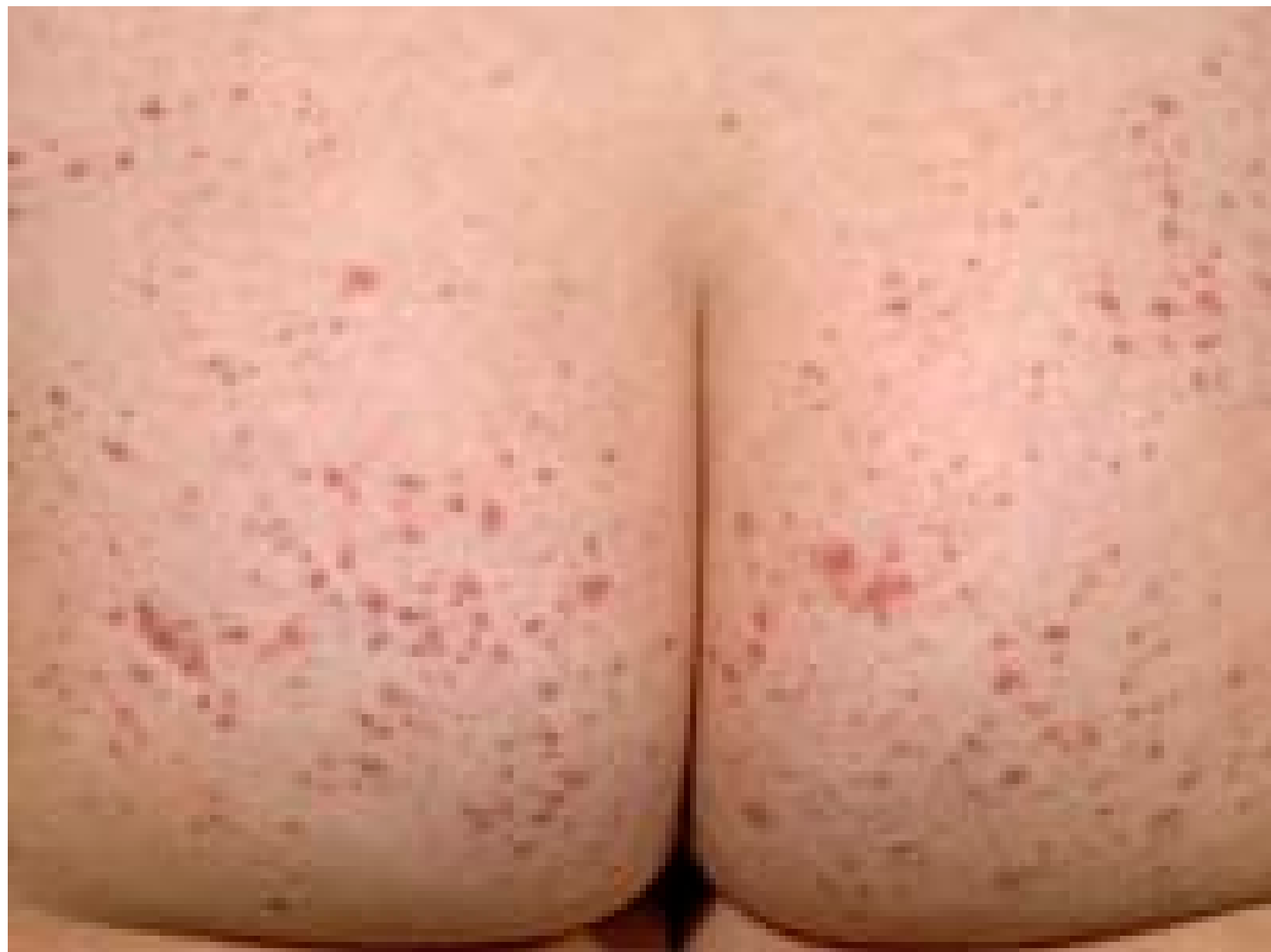


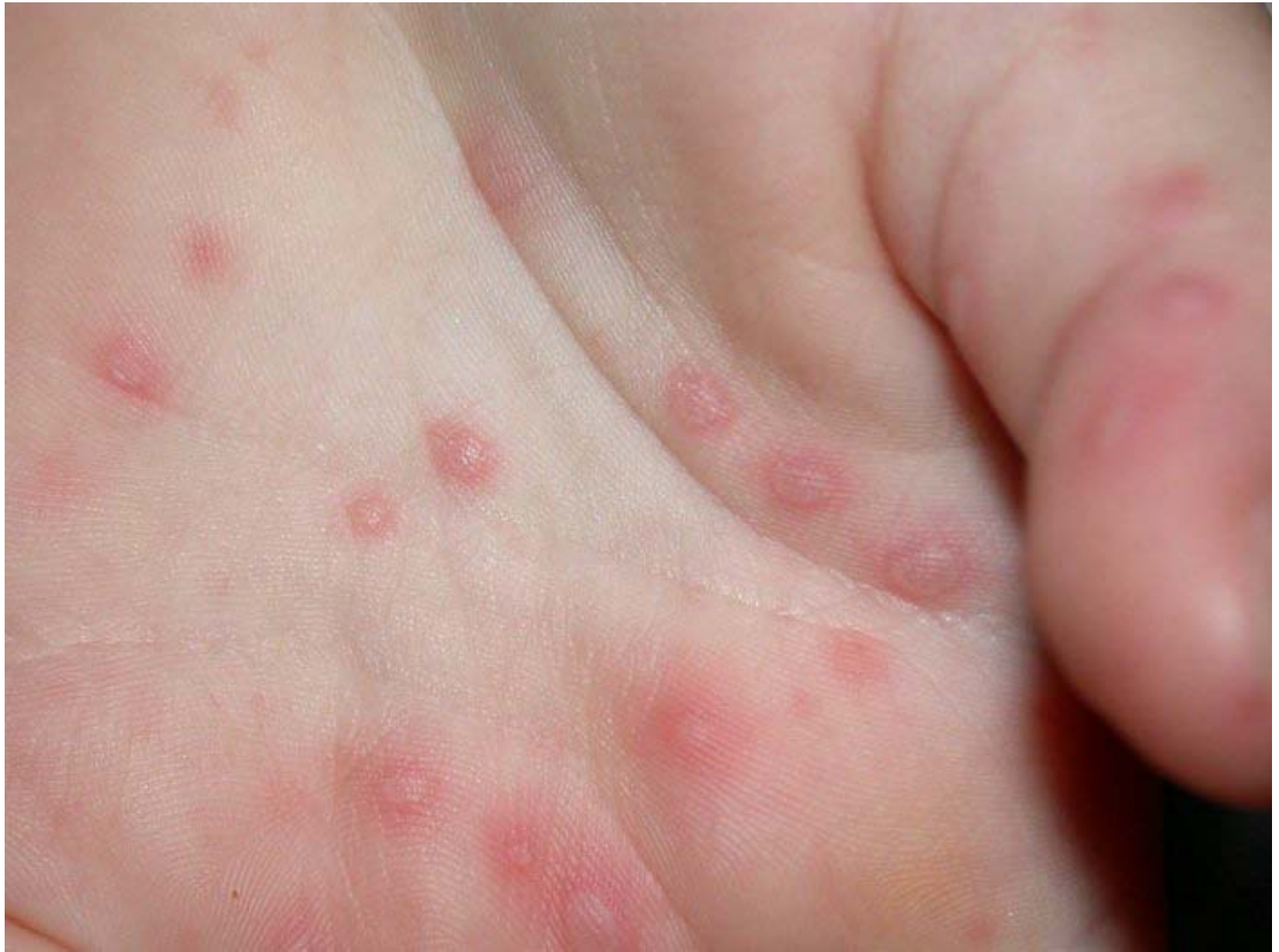


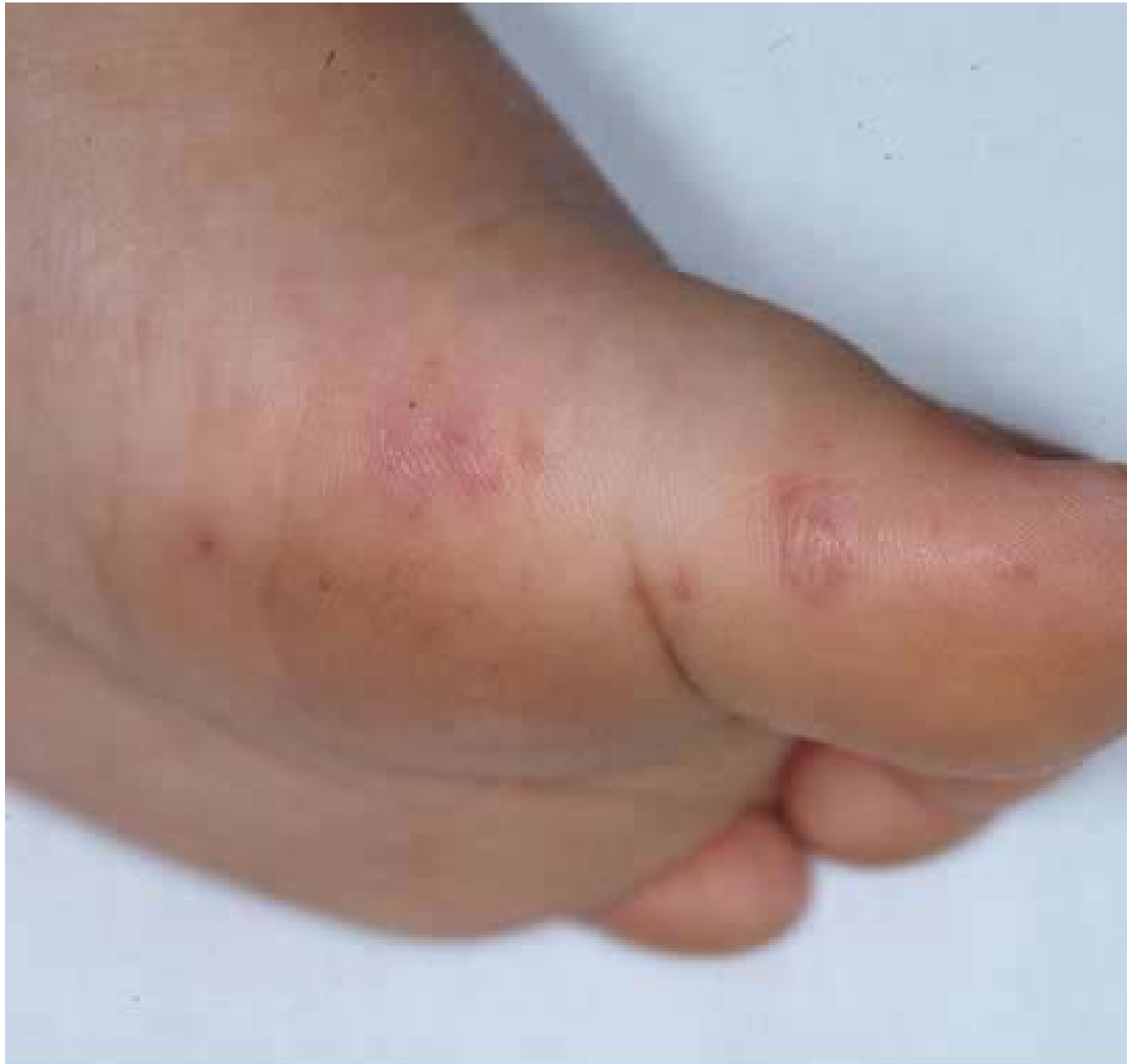

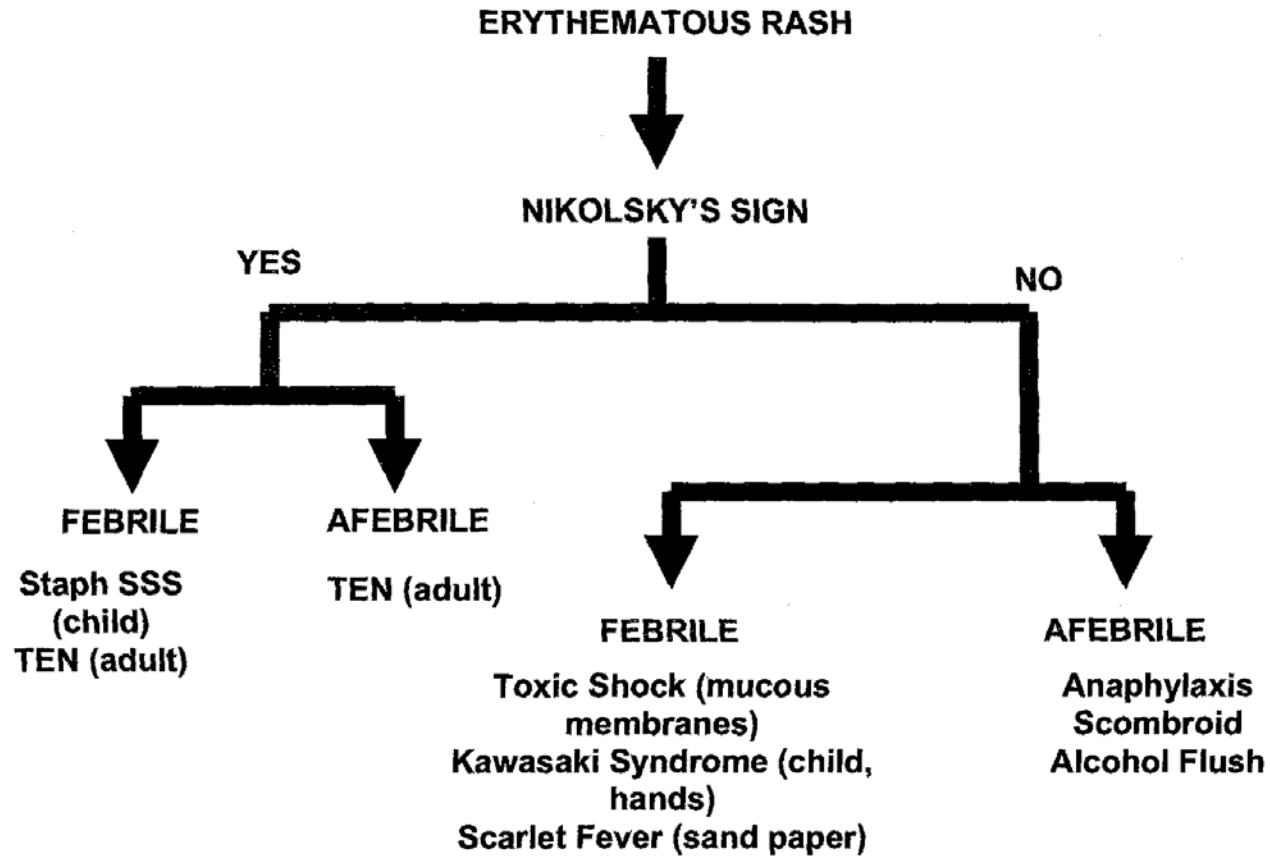
© Mayo Foundation for Medical Education and Research. All rights reserved.



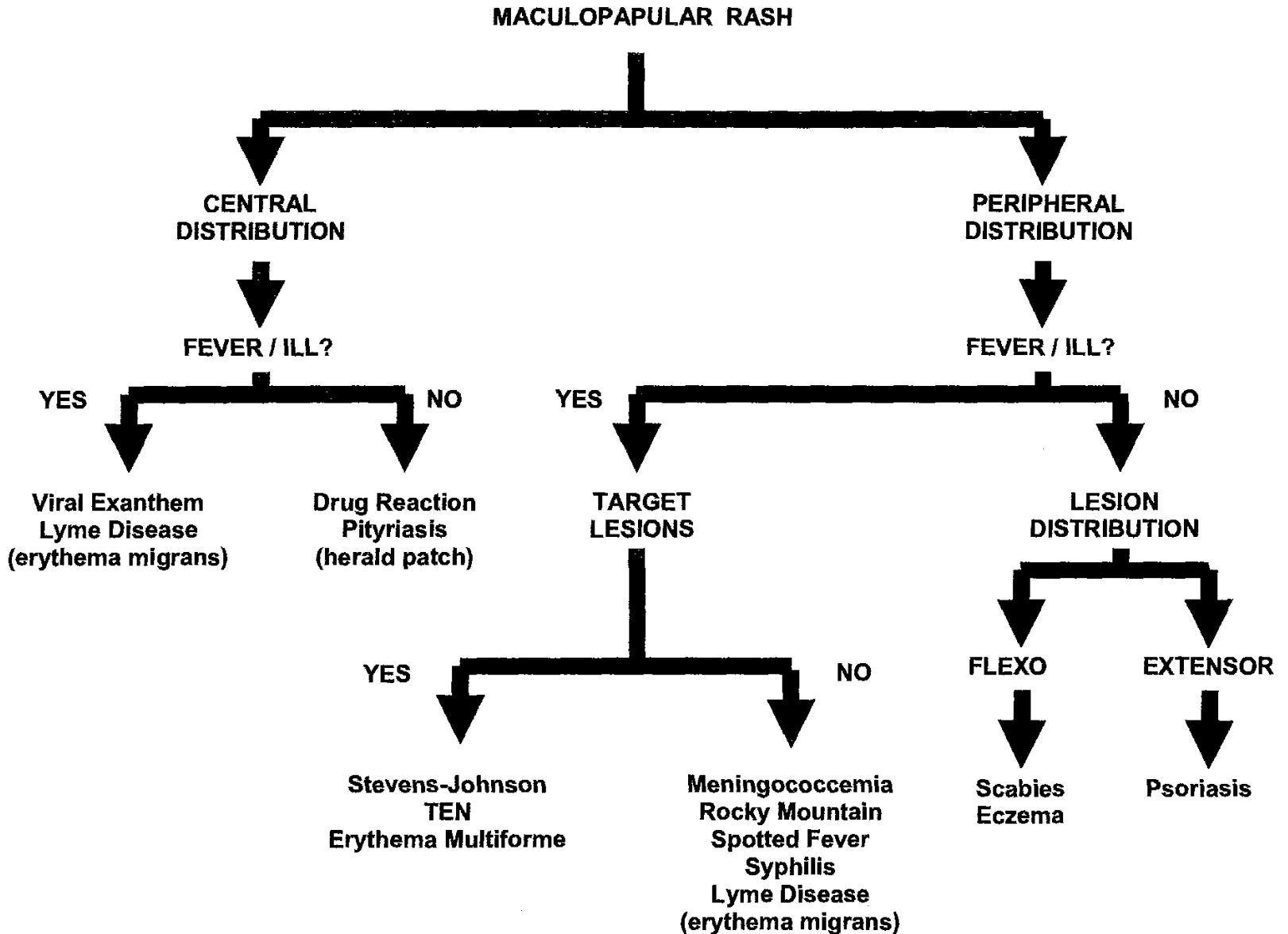




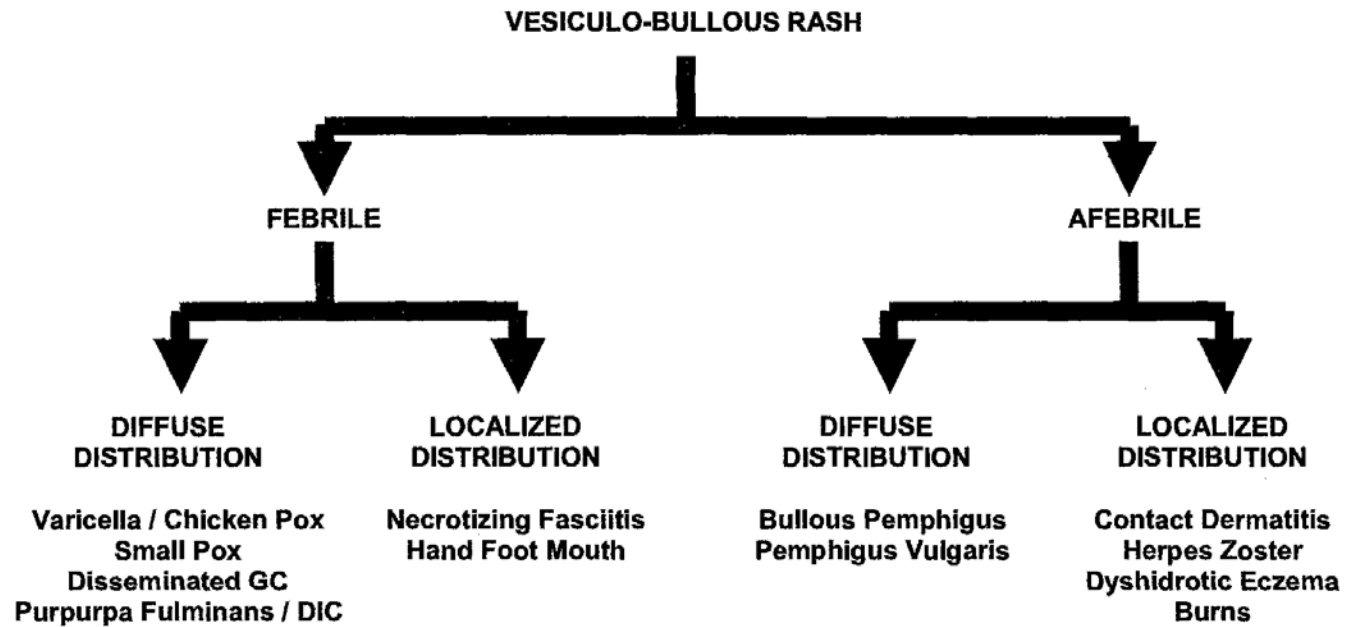
ALGORITHM ERYTHEMATOUS RASH



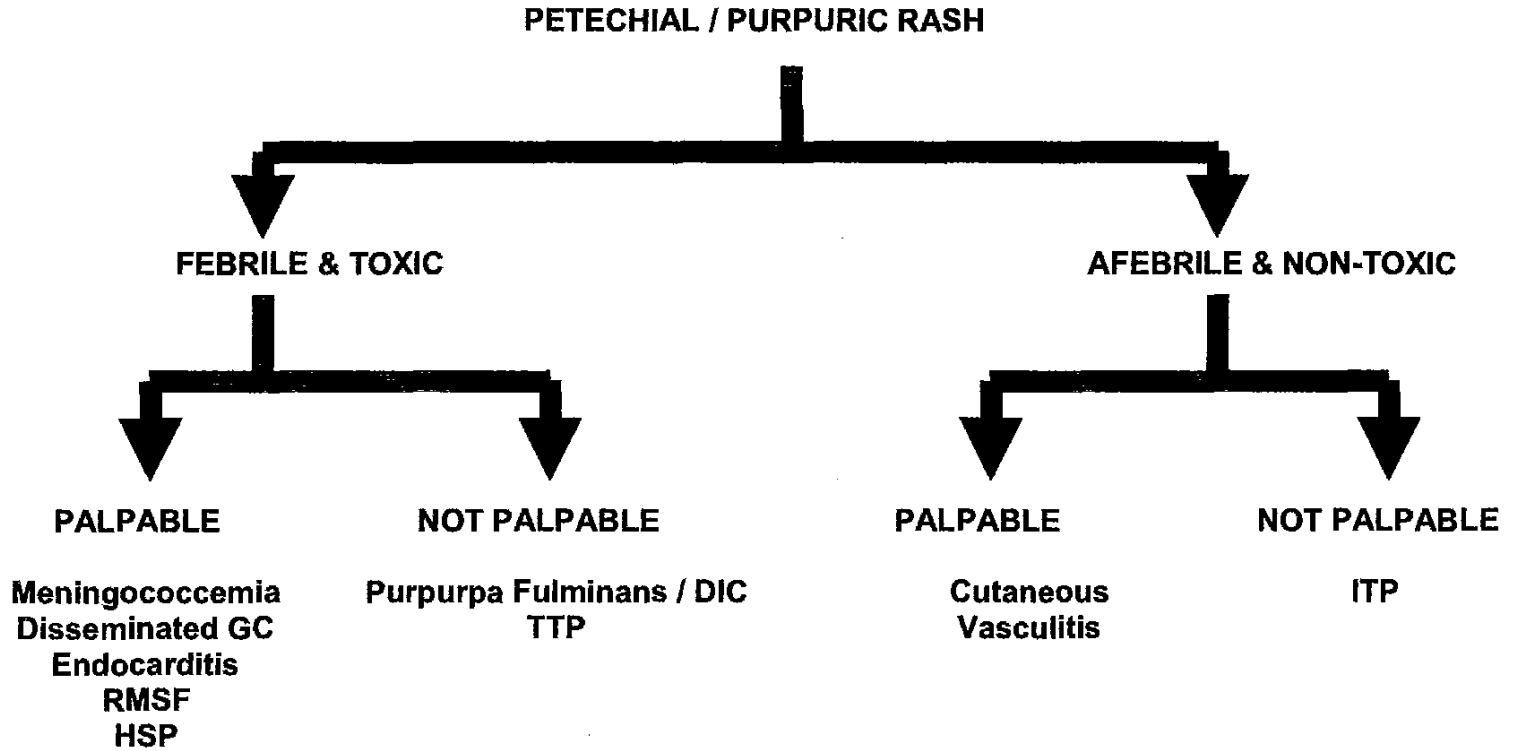
ALGORITHM MACULOPAPULAR RASH

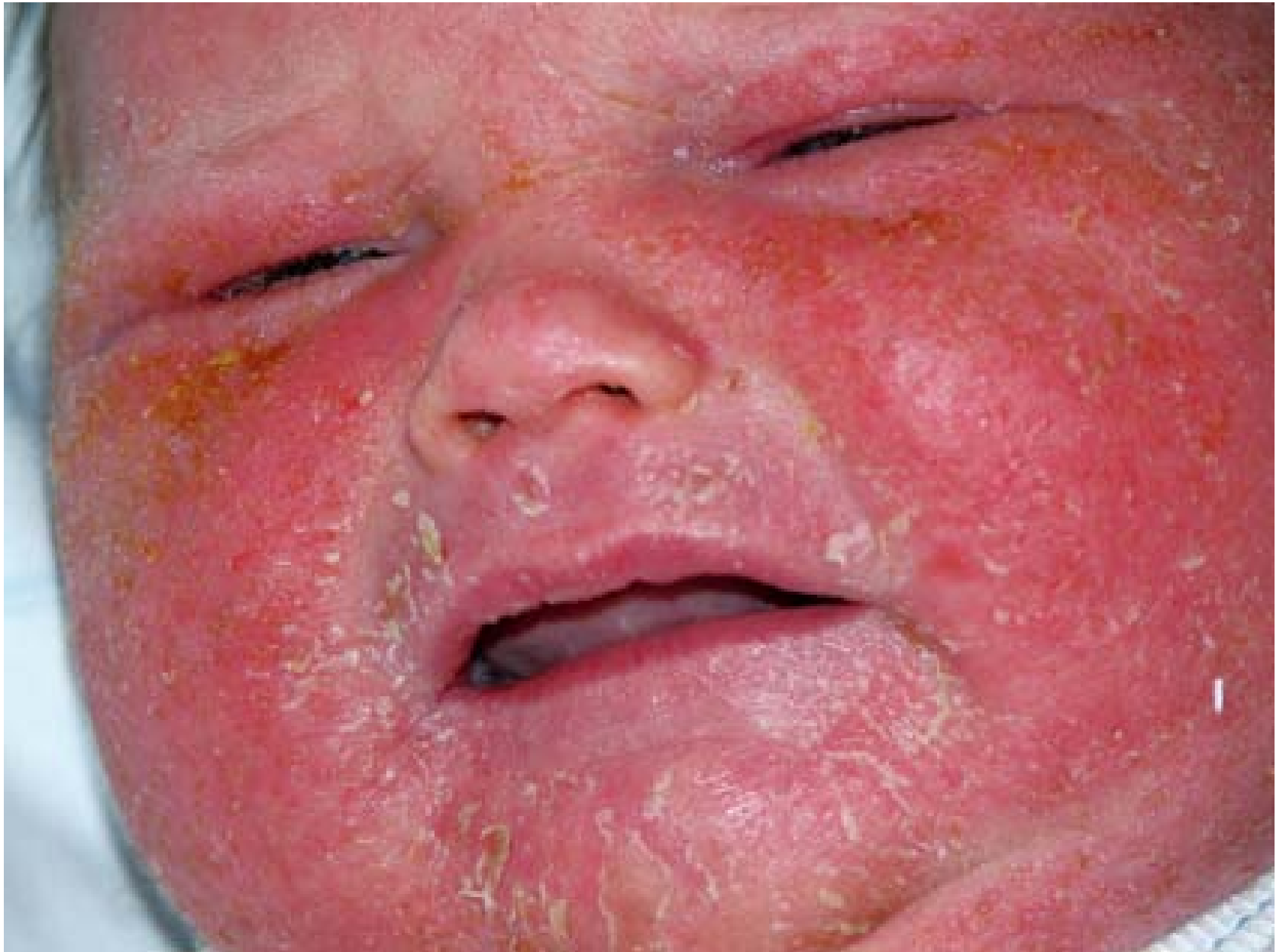

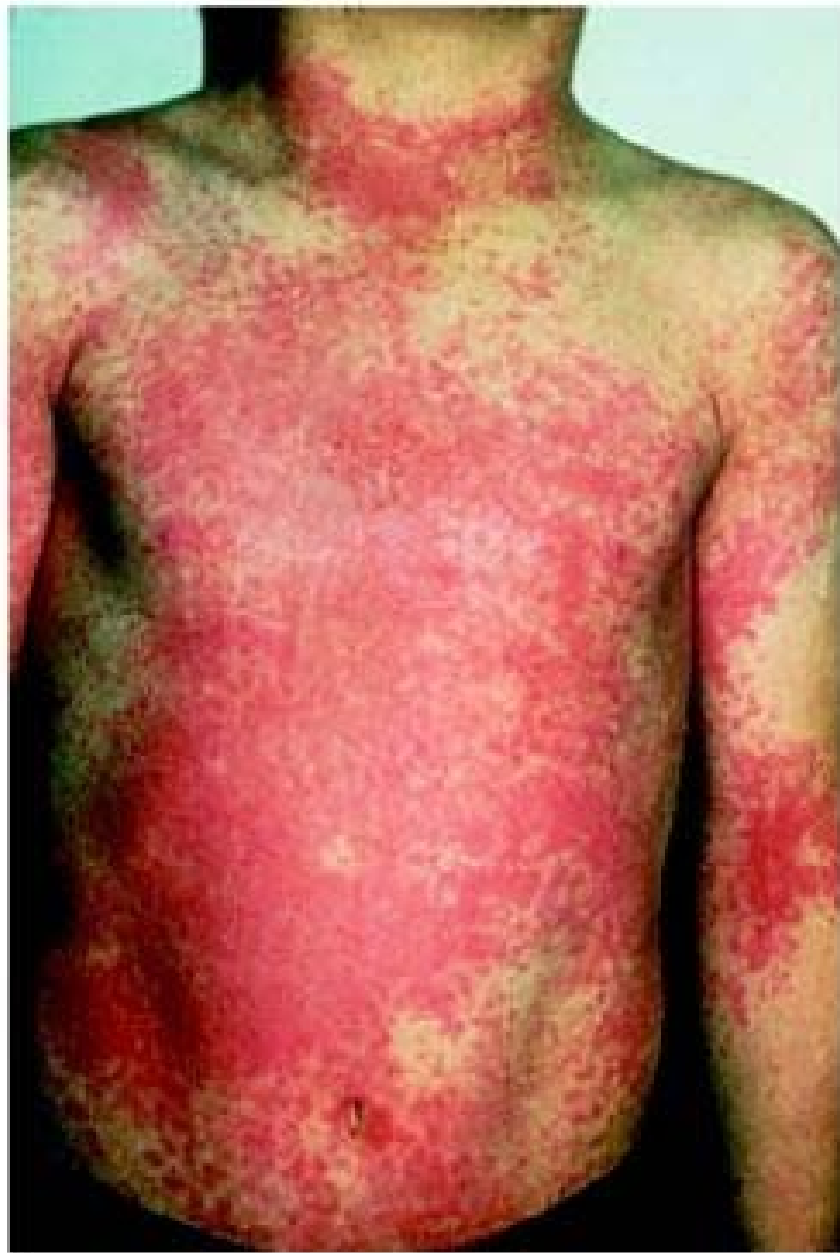ALGORITHM VESICULO-BULLOUS RASH

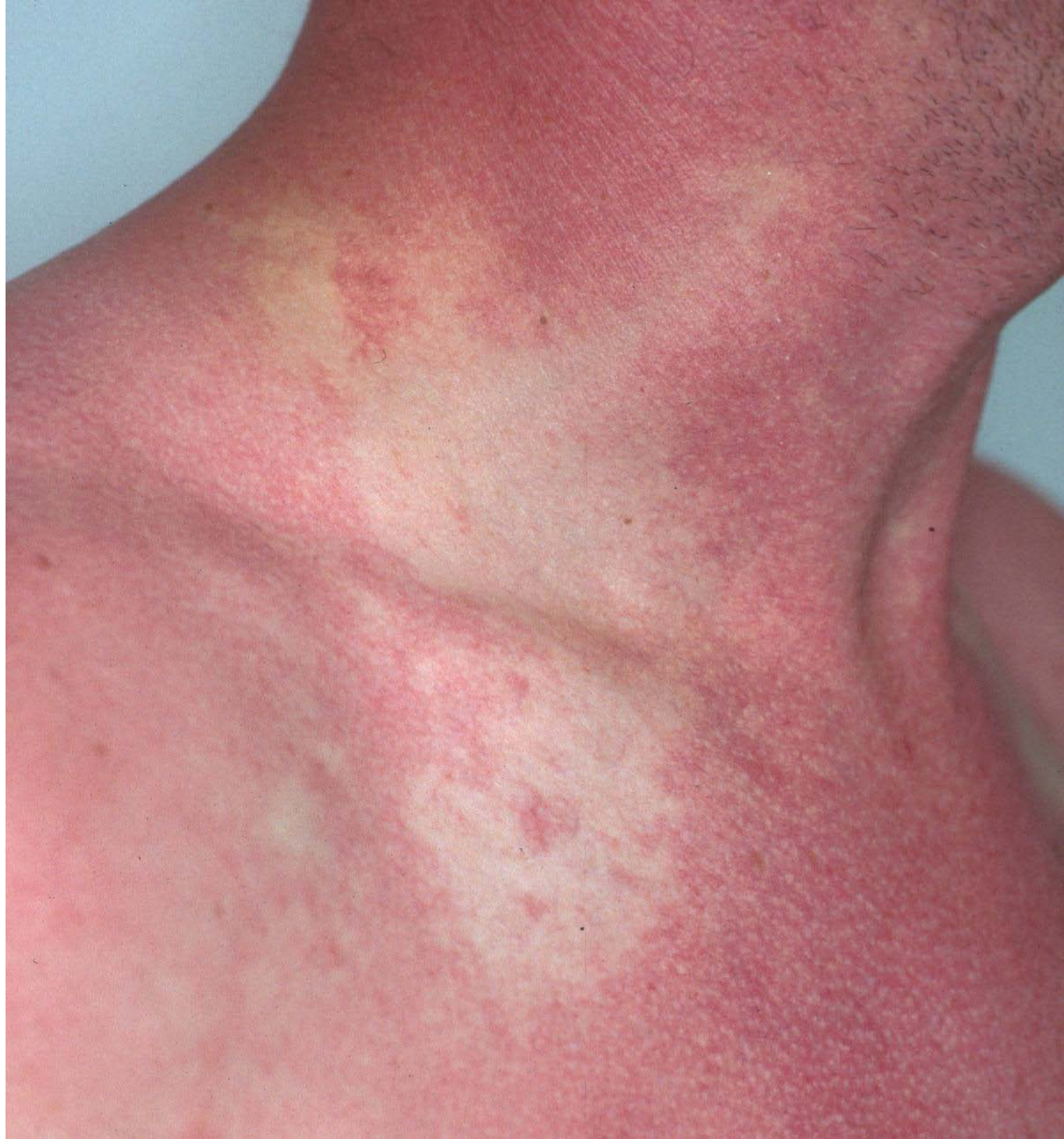

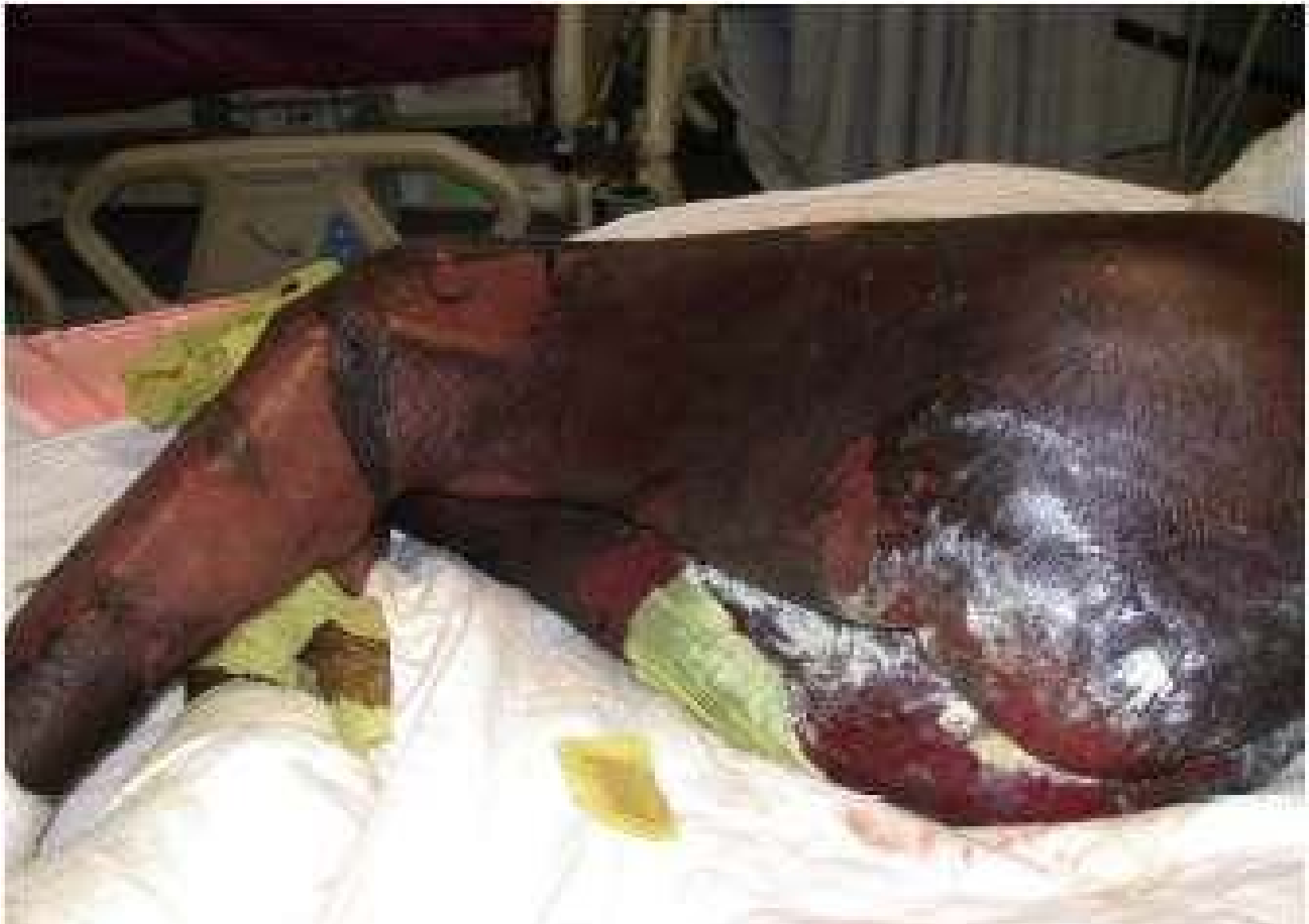ALGORITHM PETECHIAL/PURPURIC RASH

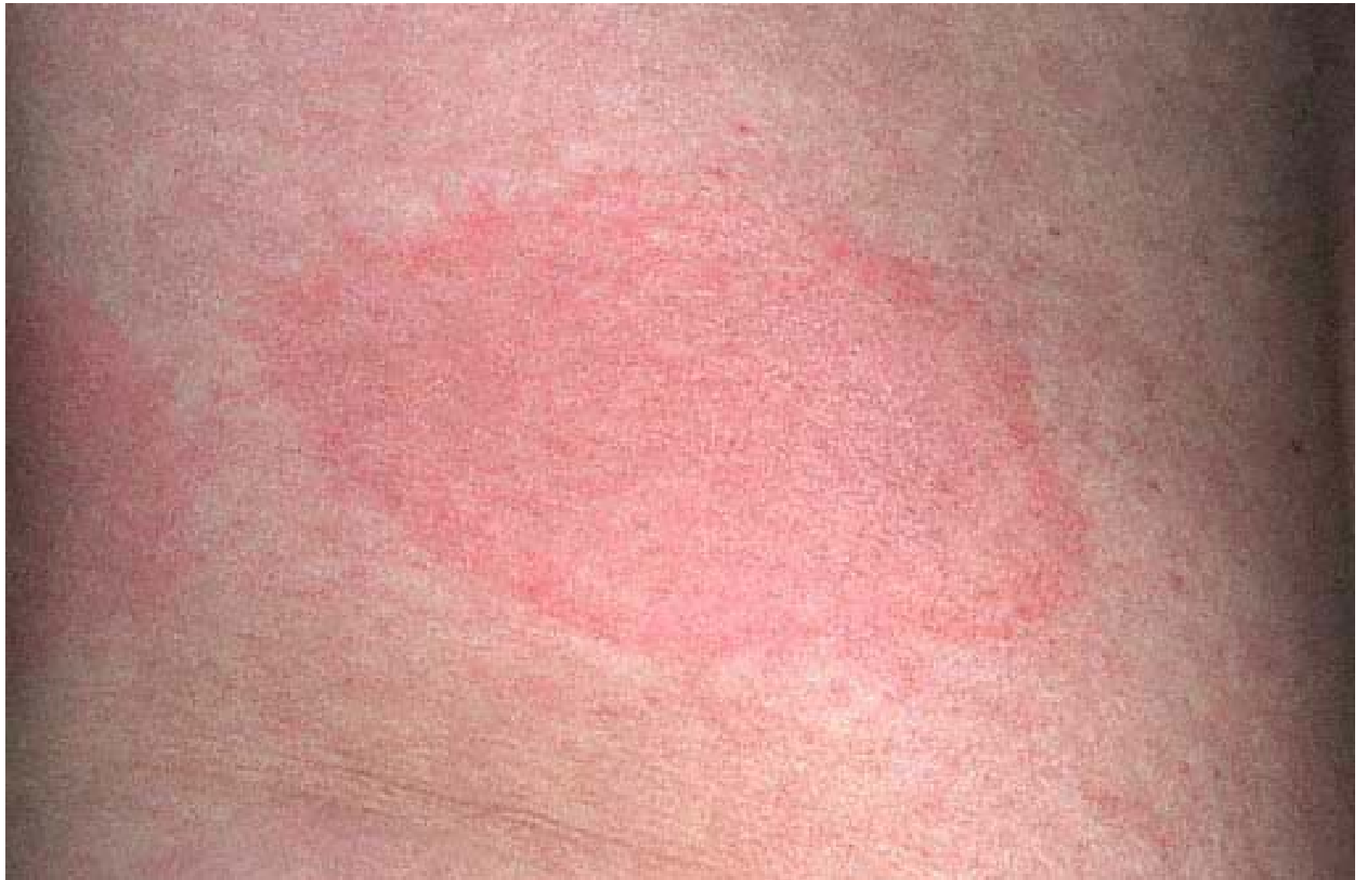


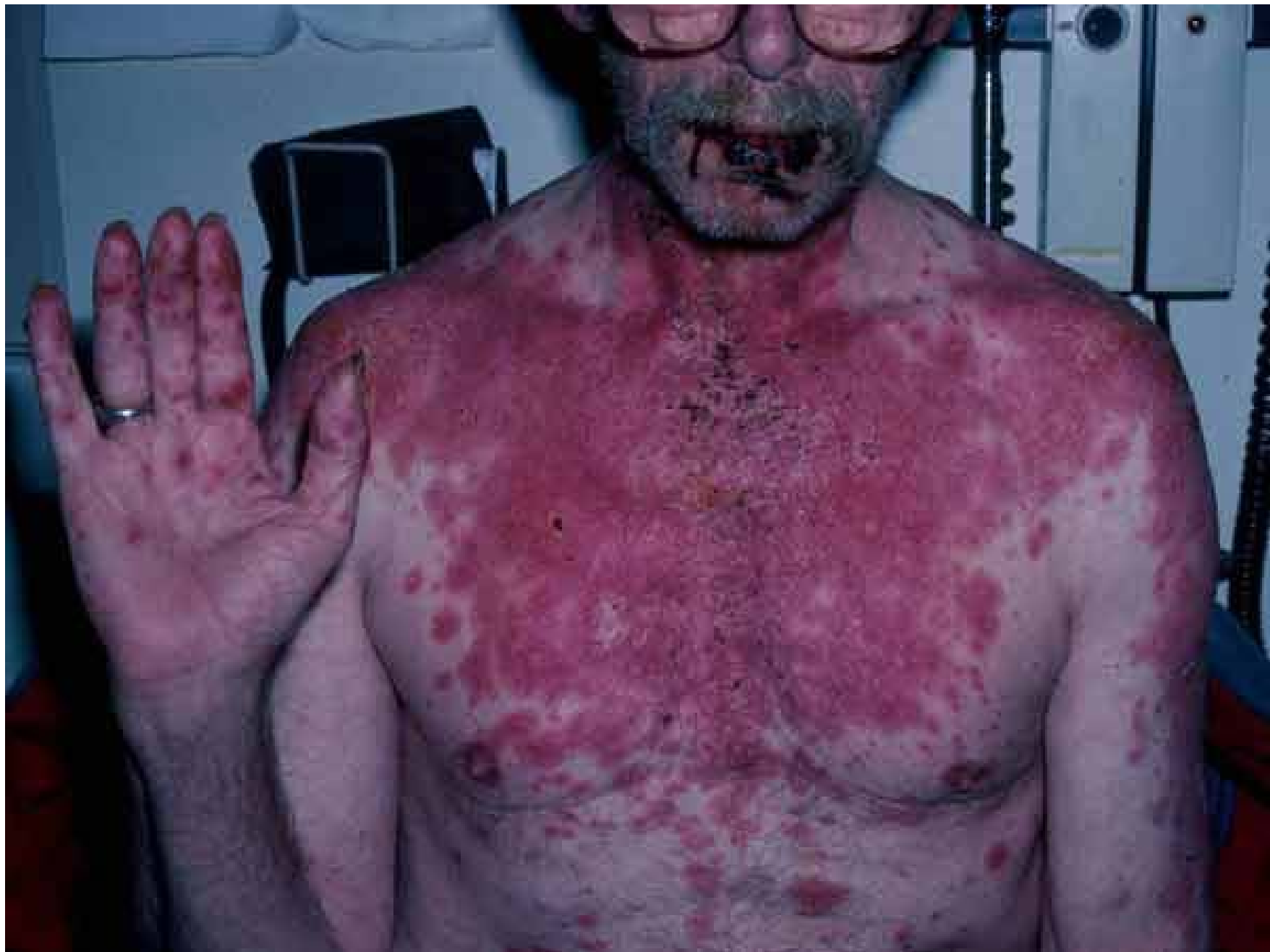


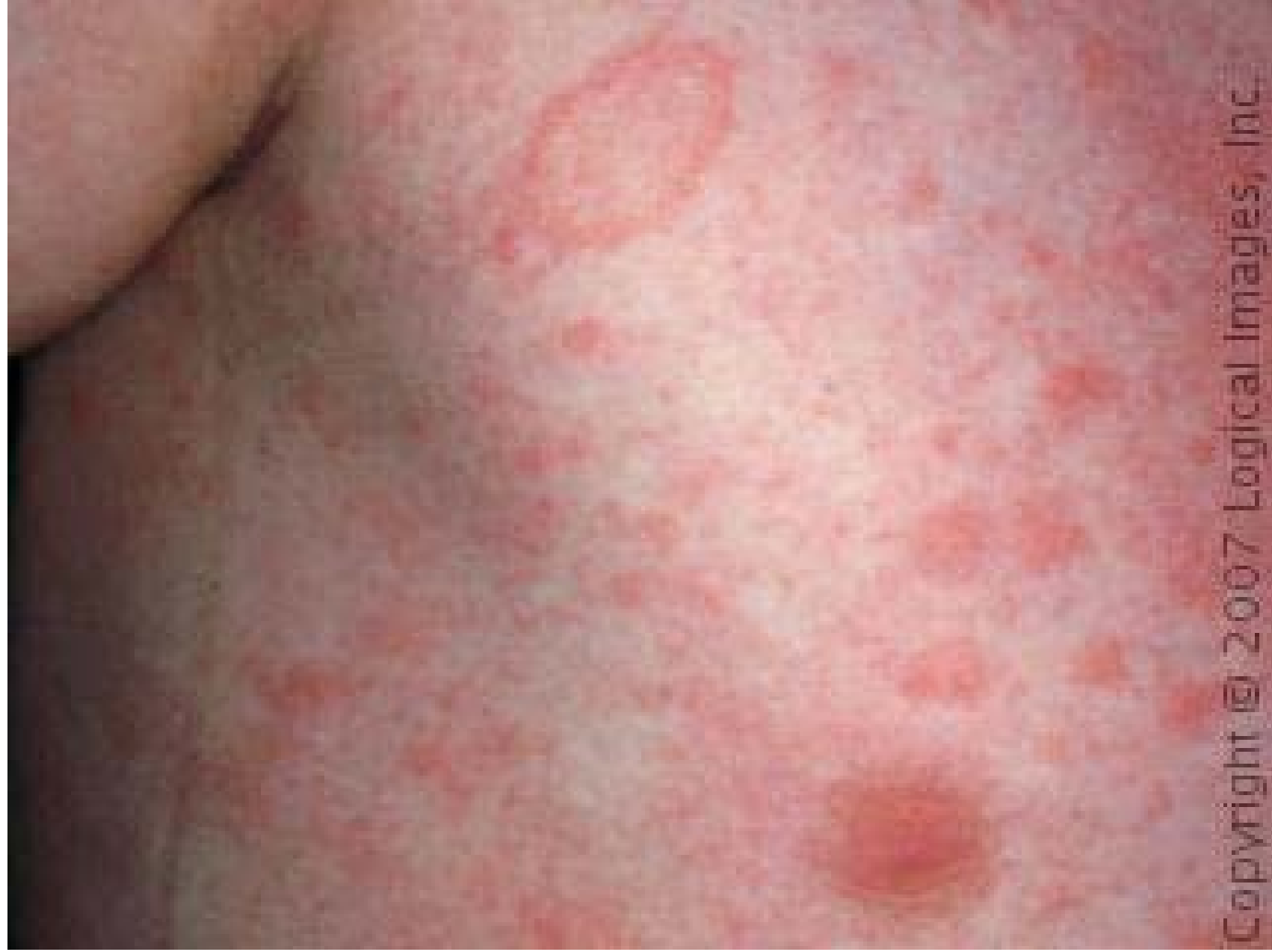




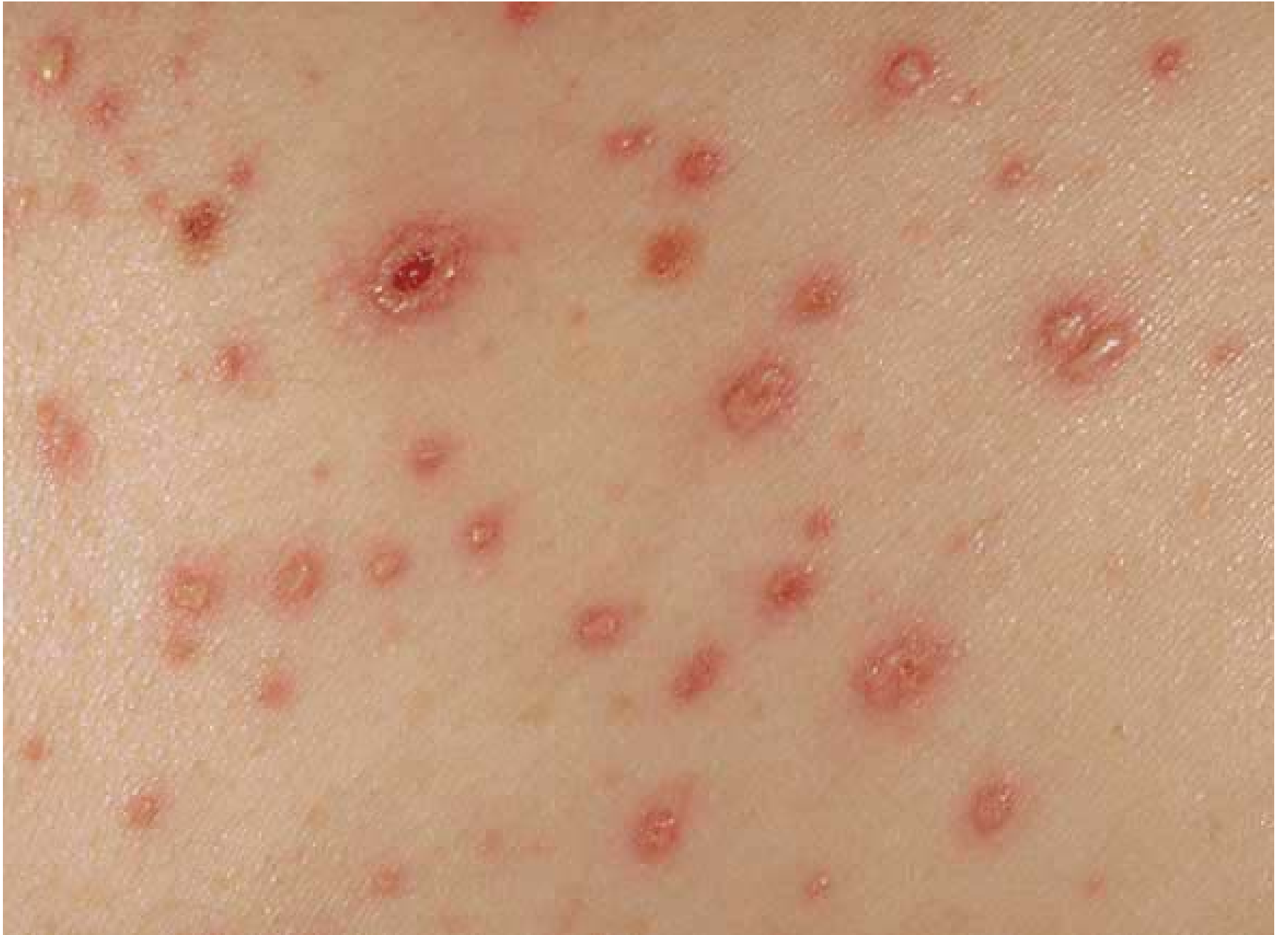


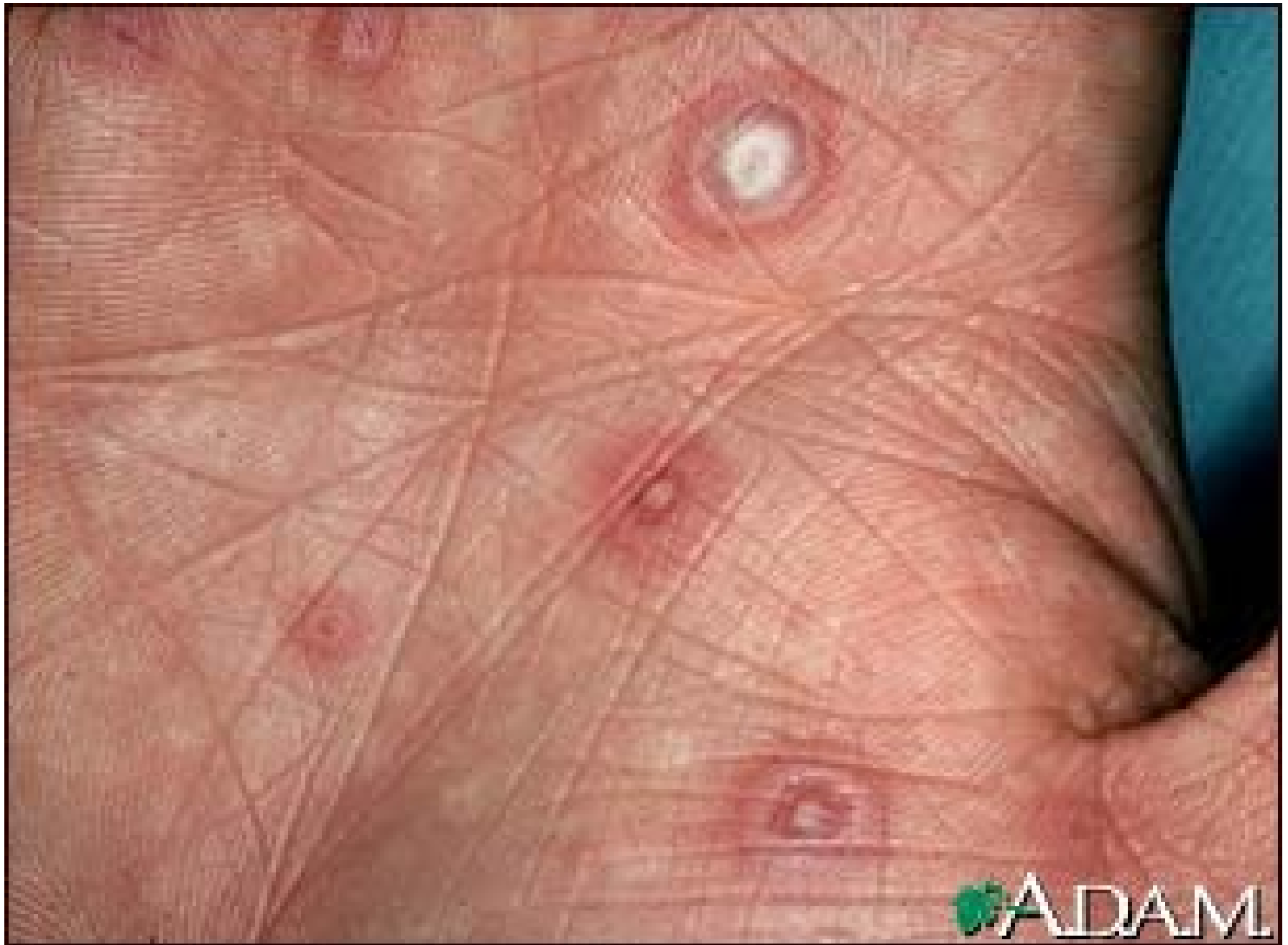

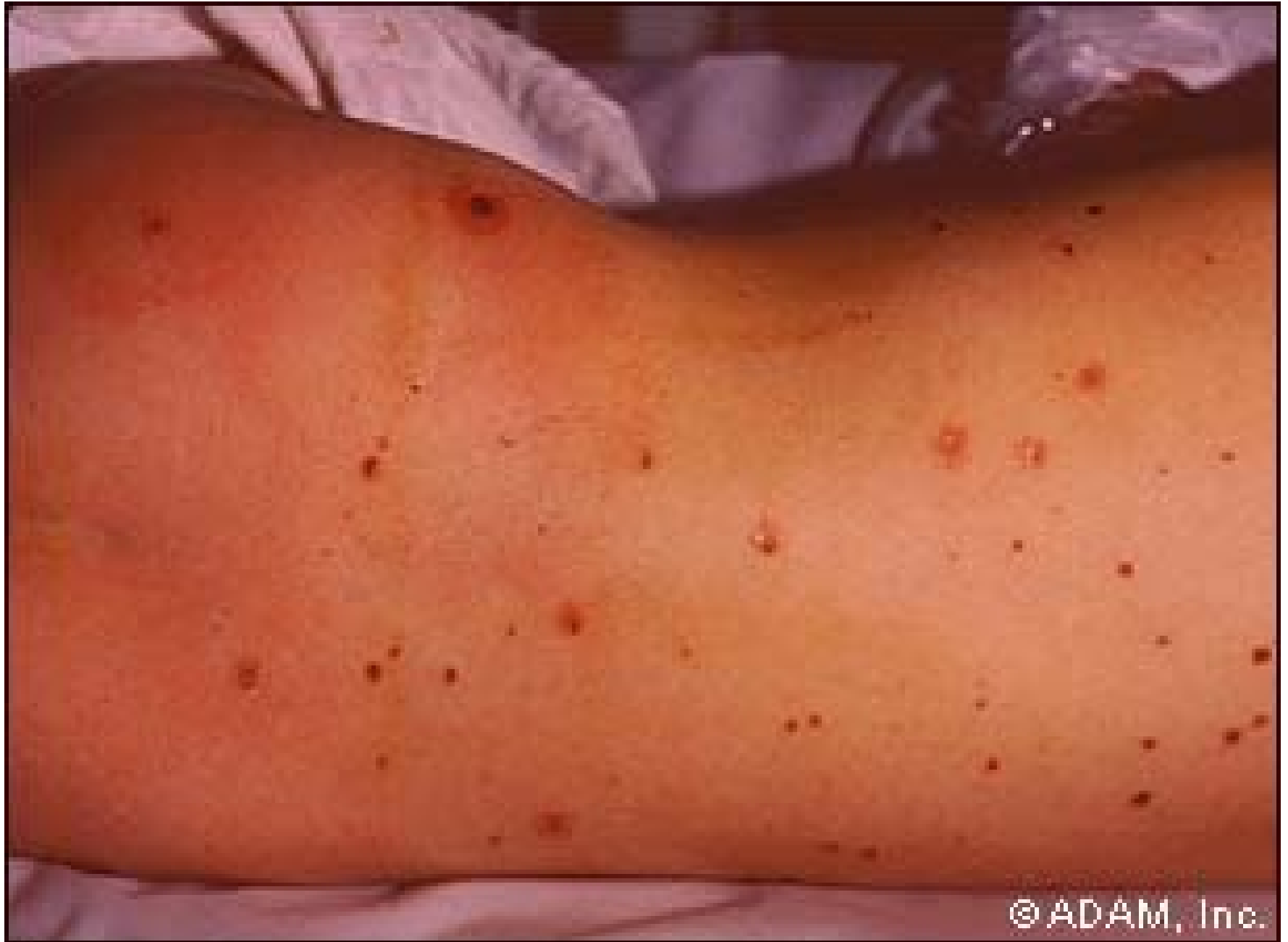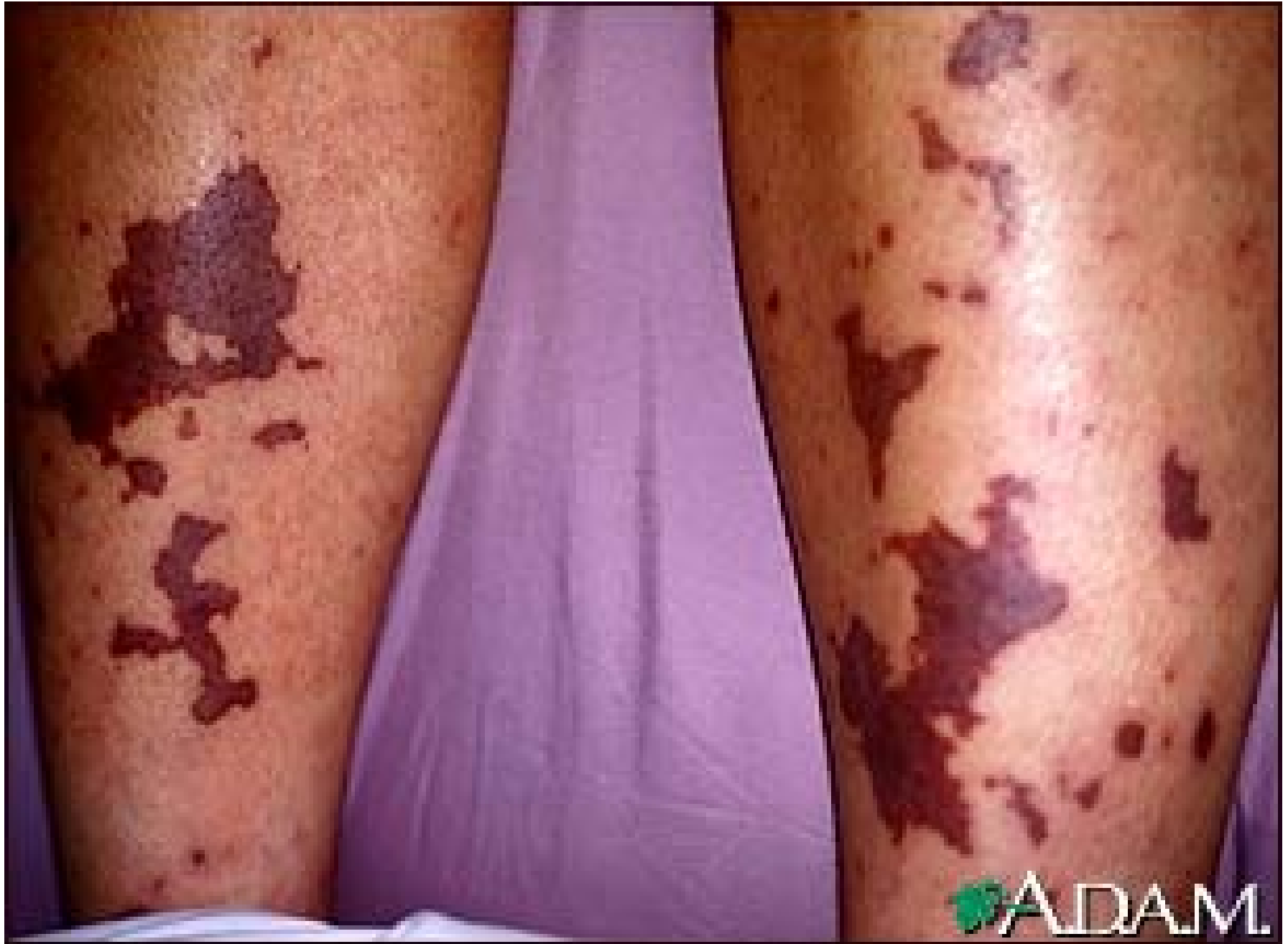Copyright © 2007 Logical Images, Inc.

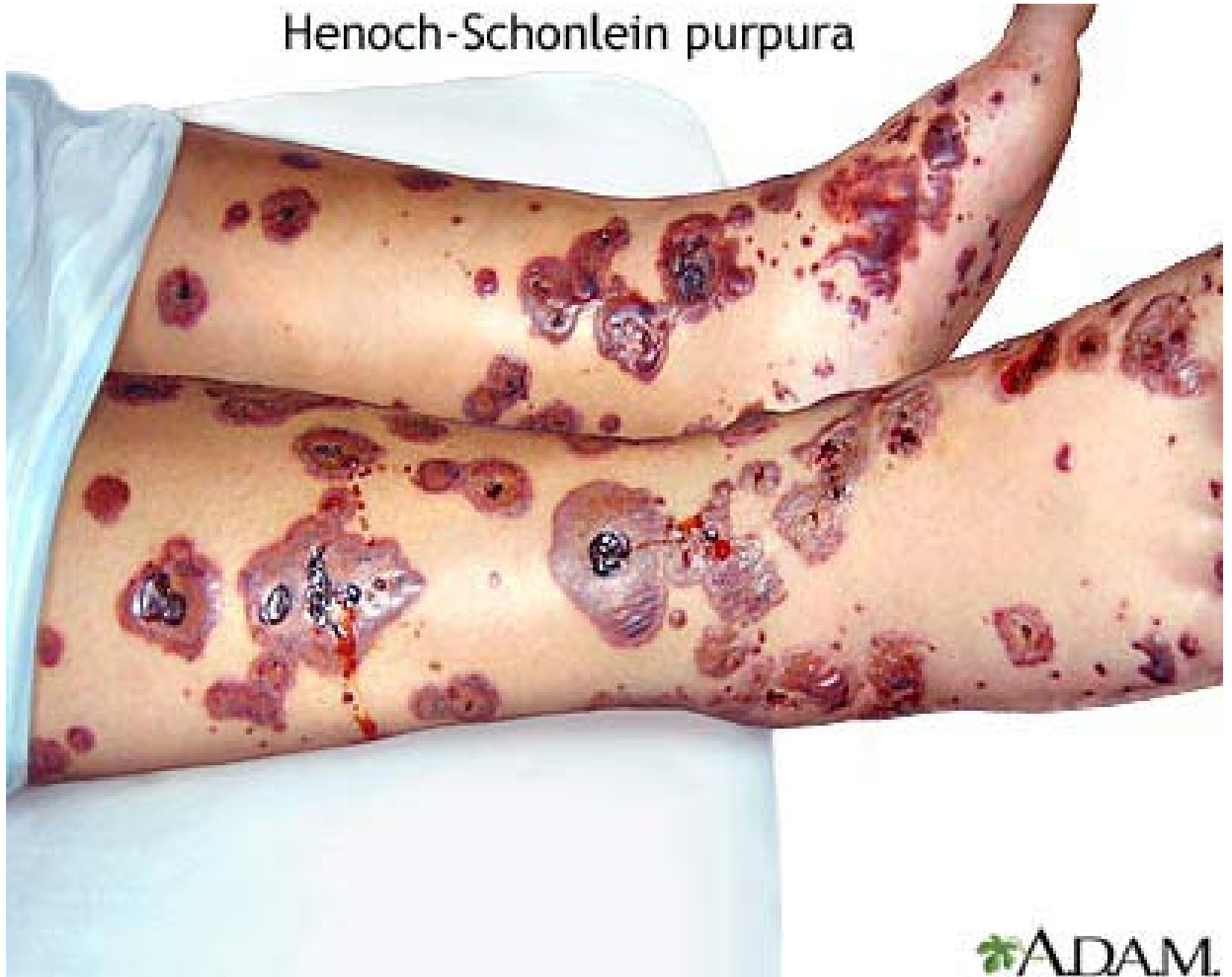


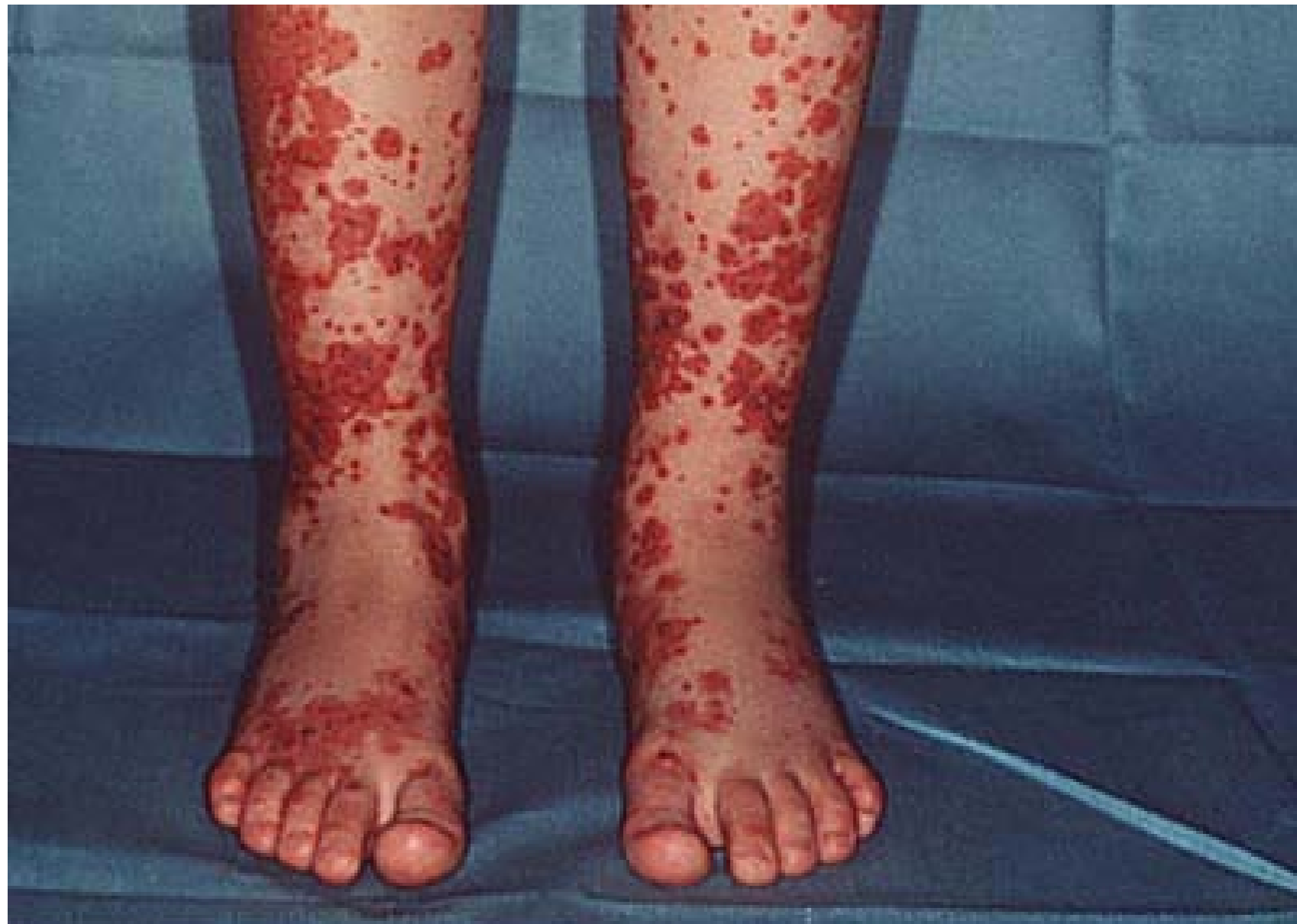




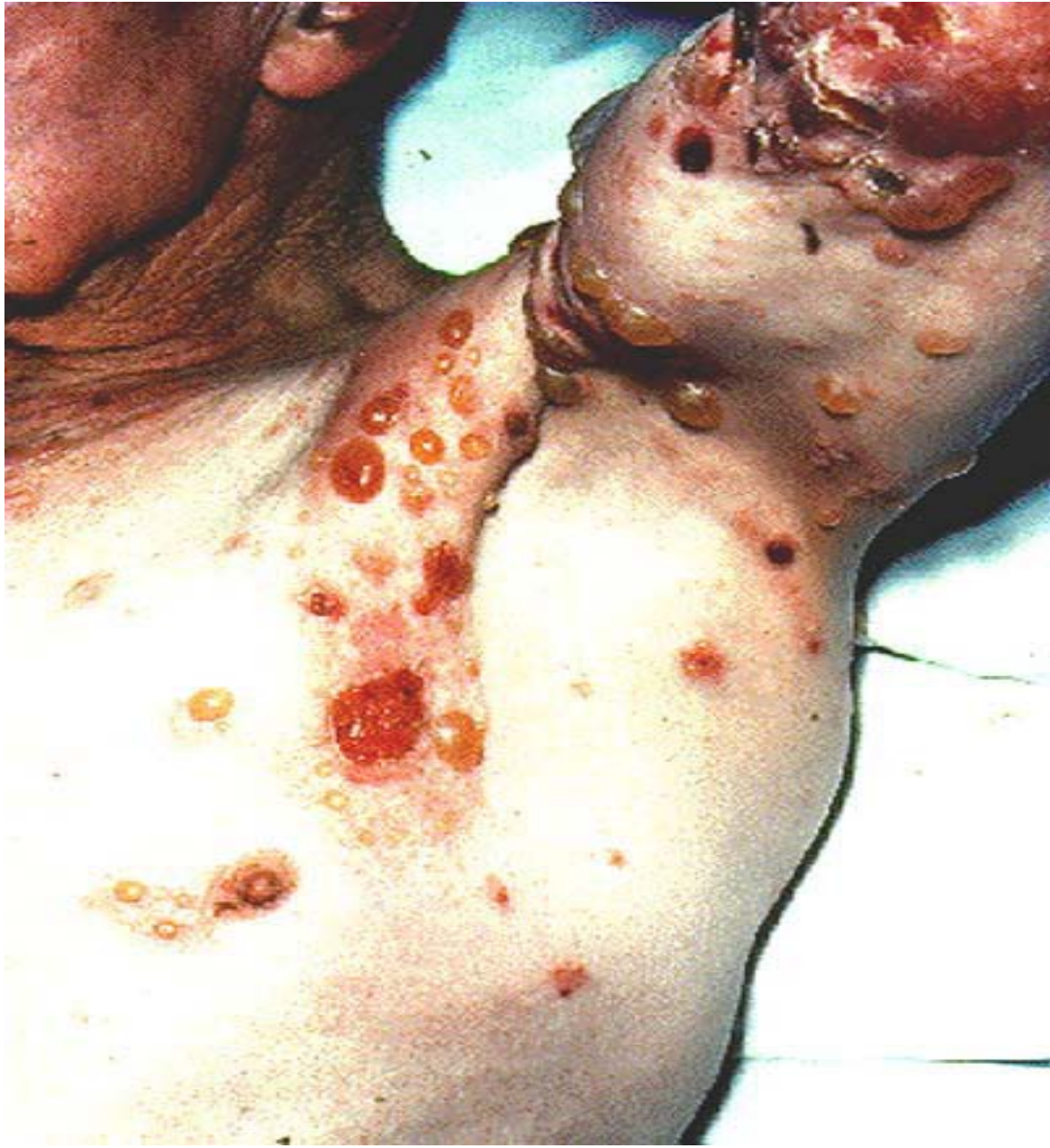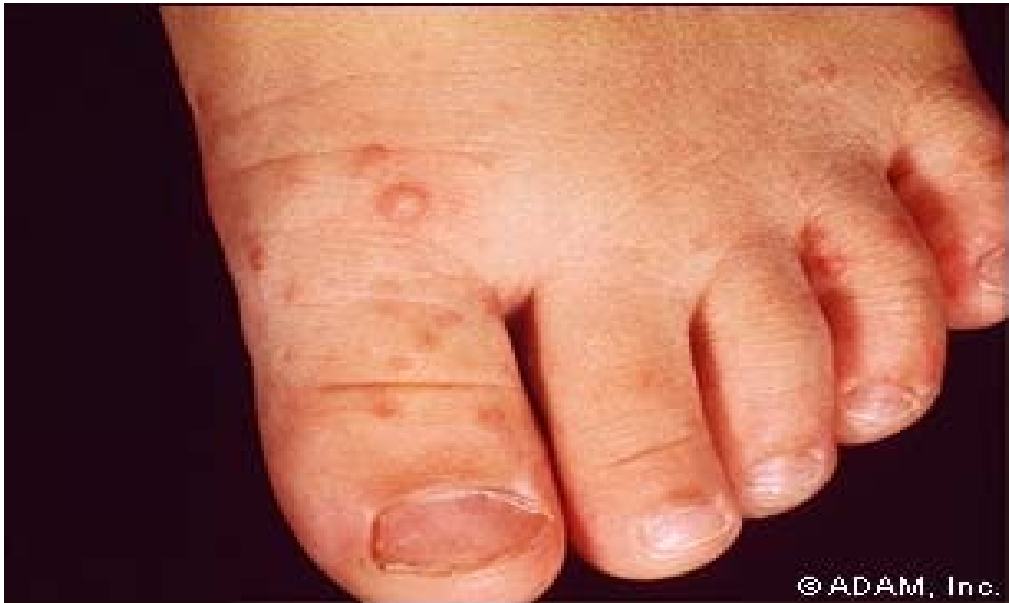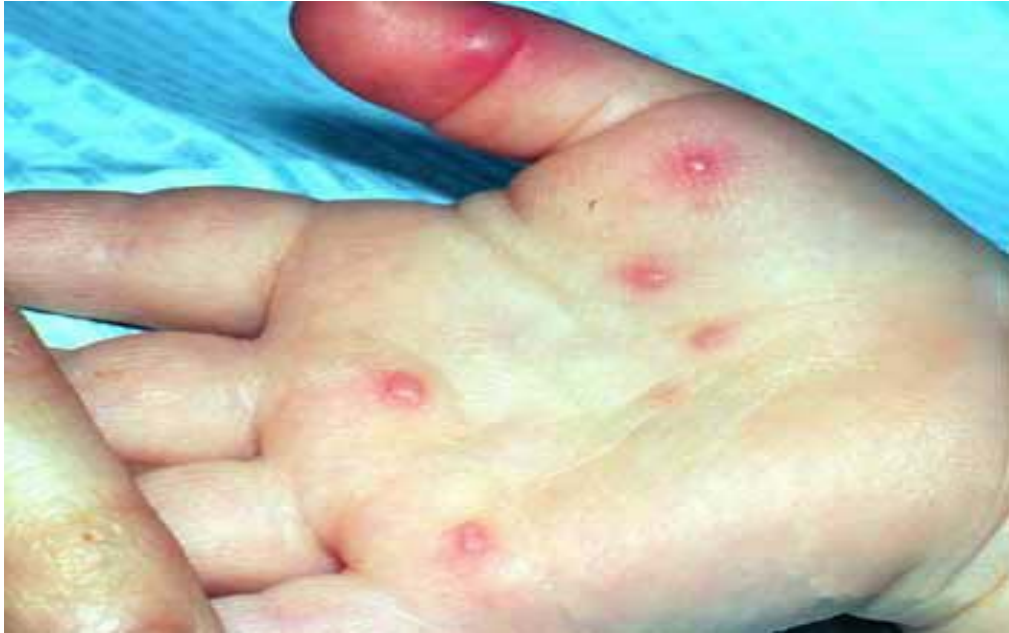Henoch-Schonlein purpura

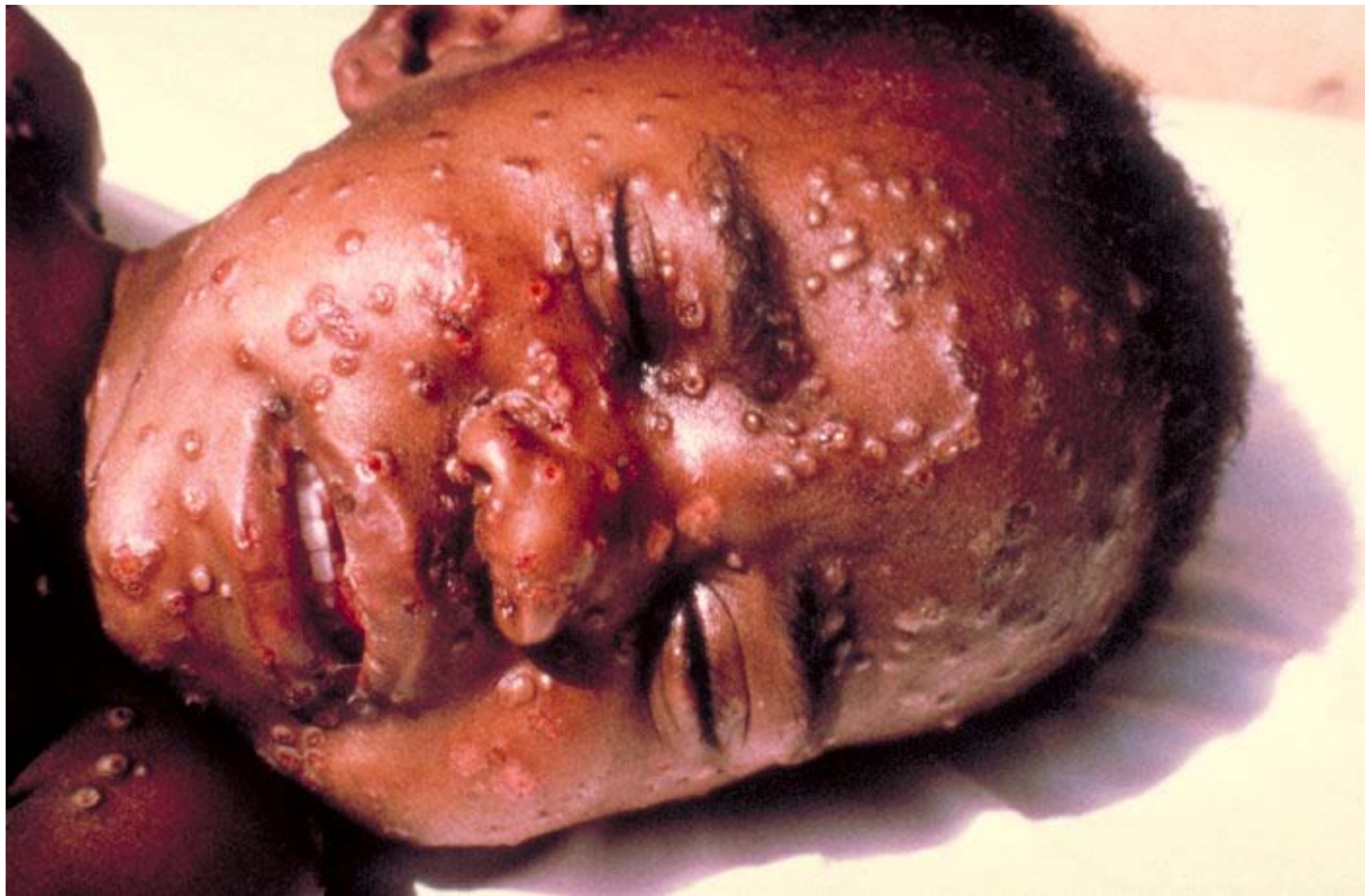



© Mayo Foundation for Medical Education and Research. All rights reserved.







MRS TECK

- M Meningococemia
- R RMSF
- S Syphilis, Scarlet Fever

- T TSS
- E Erythema Multiforme
- C Coxsacki (H-F-M)
- K Kawasacki's

THE VERY YOUNG	THE VERY OLD
Staph SSS, Kawasaki's disease, viral exanthem, meningococcemia	pemphigus vulgaris, sepsis, TEN, SJS
TOXIC	IMMUNOSUPPRESSED
necrotizing fasciitis, meningococcemia, TEN, SJS, TSS, RMSF, TTP	necrotizing fasciitis, meningococcemia, endocarditis, herpes zoster, sepsis
DIFFUSE ERYTHEMA	PETECHIAE / PURPURA
staph SSS, staph TSS, strep TSS, TEN	meningococcemia, endocarditis, TTP, ITP vasculitis, DIC, RMSF
MUCOSAL LESIONS	HYPOTENSION
EM major, TEN, SJS, pemphigus vulgaris	meningococcemia, TTP, TSS, RMSF, TEN, SJS

TEN = toxic epidermal necrolysis; **SJS** = Stevens-Johnson Syndrome, **TSS** = toxic shock syndrome, **RMSF** = Rocky Mountain spotted fever, **SSS** = scalded skin syndrome, **DIC** = disseminated intravascular coagulopathy, **EM** = erythema multiforme, **TTP** = thrombotic thrombocytopenic purpura

