



# NEWS SWALLOWING NEWS



VOLUME 19

NOVEMBER 2007

NUMBER 2

## DIRECTOR'S FORUM

### EOSINOPHILIC ESOPHAGITIS – A “NEW” DISEASE OF ALL AGES

H. Worth Boyce, M.D.

Professor of Medicine and Radiology and Director

The increasing prevalence of eosinophilic esophagitis (EE) and its complications during the past three decades provides a remarkable chapter in the history of esophageal disease. It is a disease of all ages that first appeared over 50 years ago in the medical literature and subsequently, in random reports of one or a few cases reported as a medical curiosity. Little attention was given to the disorder and there was no thought or prediction that it would emerge as the “new” disease that would begin to overshadow the popularity of GERD as the major challenge for diagnosis, therapy and clinical research by 2007.

The eosinophil is one of the white blood cells that stimulates an inflammatory response in the surface tissues (epithelium) that serve as the interface or barrier between our external and internal environments. The epithelium of skin, lungs and gastrointestinal tract develop an inflammatory response in some individuals when exposed to allergens in air (aeroallergens), chemicals or foods that are swallowed. The tissue responds by a process that causes eosinophils to be mobilized and concentrate in the tissues producing inflammation that can result in either temporary or permanent injury. The classic example is the disorder of bronchial asthma. The esophageal injury due to the surface irritants that are swallowed results in changes similar to those in the lungs seen with bronchial asthma which is caused by inhaled allergens. Therefore, the esophageal disorder has been termed “asthma of the esophagus”.

Another disease called eosinophilic gastroenteritis has been known for decades as a condition that affects primarily the stomach and small intestine. These patients rarely have esophageal involvement. On the other hand, biopsies of stomach and intestine in patients with primary eosinophilic esophagitis rarely, if ever, reveal any eosinophils. Eosinophils are not present in biopsies of the normal esophagus, but may be found in several uncommon conditions that usually are readily diagnosed by their associated features. The one entity that has created considerable diagnostic confusion is gastroesophageal reflux disease (GERD).

GERD has repeatedly been proven in some patients to be an associated disorder with EE, both in adults and children. Some patients are found to have sequelae of GERD, such as Barrett esophagus, plus the endoscopic, biopsy and positive pH test (acid reflux) findings to support the coexistence of GERD. This association is real, and so much so, that the diagnosis of EE requires either the lack of symptom response to high dose acid suppression therapy (PPI) or a normal esophageal pH study to

rule out reflux plus a biopsy that reveals greater than 15 eosinophils per high power microscopic field.

EE has been reported primarily in the United States and Canada, and also in all other continents except Africa. In our 75 patients with EE, and its' associated esophageal strictures, there have been no African-Americans. Most patients with EE are Caucasian males (65-75%) with 25-35% being Caucasian females. The average age reported in the literature is 8.6 years for children and in adults, 38 years. The youngest in our series was 8 years old and the oldest 91 years. The majority have either a personal or family history of some allergic condition, usually of skin, asthma or food allergy.

The clinical manifestations are typically different in children and adults. Children often present with abdominal pain, vomiting and regurgitation, difficulty swallowing (dysphagia), sitophobia (fear of swallowing certain solid foods) or symptoms suggesting GERD. Adults are more likely to present with dysphagia, typical or atypical GERD symptoms, a history of being a slow eater since childhood or acutely with an esophageal food impaction by meat, bread or pasta. Recent clinical reports suggest strictures associated with EE are beginning to be more often the cause of food impaction than those due to acid reflux. The wide use of the excellent acid suppressing drugs (PPI's), both by prescription and over-the-counter, is reducing the incidence of reflux-related strictures. Weight loss in older children and adults is uncommon since diet modification by changing to liquids and soft foods allows nutritional compensation in most patients.

The diagnosis of EE is best confirmed by endoscopy and biopsy. Most patients with longstanding disease complicated by a stricture with dysphagia will have changes in the esophageal lining or mucosa that are typical for this disease. Such changes include linear creasing or furrows, small white surface patches (that represent clusters or abscesses of eosinophils), ring strictures or a narrow tube-like esophageal constriction, and a rather stiff mucosa that tears easily by pressure of the endoscope or after dilation. In spite of these typical findings, some patients are reported to have a normal endoscopy; therefore, multiple normal esophageal biopsies from proximal mid and distal esophagus are necessary to rule out the diagnosis of EE. None of our patients with EE and strictures have had normal mucosa.

The natural history of EE is not yet known, but some reports indicate that either stability, progression, or improvement of dysphagia may occur without therapy, but rarely

## EOSINOPHILIC ESOPHAGITIS – A “NEW” DISEASE OF ALL AGES (continued)

complete resolution for the stage of the disease with a stricture.

Treatment in children with food elimination diets is not often successful except for those with very specific food allergies. Elemental diets using amino acid formulas have been successful in some, but such formulas are not tolerated when oral feedings are attempted because they are not palatable. Oral systemic steroids are successful, but are not recommended due to long-term side effects. Two topical steroid preparations of proven benefit that are used in asthma by inhalation have been reported useful for EE when used over courses of 6 to 8 weeks. If the initial response is satisfactory, a recurrence of symptoms is likely within 6 months after discontinuation of treatment. Fluticasone propionate and budesonide are used for asthma or inhalation therapy, and also produce temporary responses in many patients with EE when swallowed and not inhaled. Research is needed to determine the proper duration and dosage of therapy with these drugs. Other agents are currently being introduced in clinical research programs and may offer more permanent responses.

In our experience in treating strictures with EE, the proper use of esophageal dilation provides satisfactory initial relief in 3 to 4 dilation sessions. Dilations must be done in a more gradual incremental fashion in order to minimize post dilation pain. We have not observed any major complications or perforations in the 75 patients we have treated over the past 17 years. The combination of initial dilation plus a course of topical steroid or other newer drug therapy may eventually be the therapeutic options of choice. When GERD is proven to be an associated problem, the proper therapy to add is adequate acid suppression using one of the PPI agents.

The possibility of EE should be considered strongly in any patient, especially in a Caucasian male of any age, who has dysphagia with solid foods and in children with an aversion to solid foods.

*Stay tuned – a better understanding and more effective therapy for EE are on the horizon!*

## UPPER ESOPHAGEAL SPHINCTER ANATOMY AND FUNCTION

Milton C. Johnson, M.D., Associate Professor of Medicine

This is the first of a series of “CSD News” articles on the anatomy, function, and disorders of the upper esophageal sphincter that we will introduce in the coming year. The importance of the upper esophageal sphincter is often overlooked. Radiologists and endoscopists often spend little time assessing the upper esophageal sphincter region during their respective radiologic and endoscopic examinations for other indications. Dysphagia (difficulty swallowing symptoms or sensation of hang-up) may be related to oral, pharyngeal and esophageal abnormalities of structure or function. Upper esophageal sphincter (UES or cricopharyngeus) structural or functional abnormalities may also be a significant cause of bolus hang-up or delay or the reason for symptoms of aspiration or “choking”. Therefore, it is important that we understand the role of the UES in swallowing. This first article in our UES series will review the anatomy and function of the UES.

The esophagus is divided into three distinct functional portions. The most proximal (upper) portion is the upper esophageal sphincter (UES) or cricopharyngeus. This area is referred to as a “high pressure zone” due to the “squeeze” provided by the UES when closed. The middle portion is the body of the esophagus. This area contains the 25 cm (10 inch) length tubular esophagus. Solid and liquid boluses are propelled (pushed) through this complex tube into the stomach. The most distal (bottom) portion is the lower esophageal sphincter (LES). This region is also a “high pressure zone” that relaxes and allows swallowed solids and liquids to enter the stomach but promptly tightens to resist reflux into the esophagus.

Anatomically (or in relationship to other organs and structures), the upper esophageal sphincter (UES) is located at the distal or bottom extent of the pharynx (back of throat) and the proximal (top) margin of the upper cervical (neck) esophagus. The primary purpose of the UES is to serve as a “barrier”. As a barrier, the UES protects against the regurgitation (spontaneous backflow of esophageal and gastric contents not associated with nausea) of food particles and liquid into the airway. In addition, the UES prevents the entry of excess air into the digestive tract.

The UES is composed of three distinct muscle groups. The **cranial cervical esophagus muscles** serve as a minor component of both the upper two thirds and the lower one-third of the high pressure zone produced by the UES. Posteriorly, (behind and

toward the spine) and laterally (toward the side, both right and left) the **cricopharyngeus muscle** constitutes a significant portion of the UES. In fact, the cricopharyngeus muscle is responsible for nearly the entire lower one-third of the high-pressure zone produced by the UES. The upper two-thirds of the UES high-pressure zone is predominantly produced by the **inferior (pharyngeal) constrictors** muscle group. Anatomically, the posterior and lateral span of the cricopharyngeus muscle produces a “sling” appearance when viewed from back-to-side and front-to-back. Anteriorly (front), the cricopharyngeus muscle inserts or attaches to the cricoid and thyroid cartilages. The cricopharyngeus, inferior pharyngeal constrictor and cranial cervical esophagus muscles are all striated muscles (containing long muscle fiber bands that are bundled). Striated muscles are under “voluntary control” by our nervous system and may be “trained” and strengthened if injured or weakened following a catastrophic event such as a stroke, head trauma or starvation and disuse states. The results of extensive studies of human anatomy and physiology or function of the UES leaves no doubt that the cricopharyngeus muscle is the primary muscle of the UES.

The opening of the UES is governed by the forward, upward movement of the larynx following contraction of the hyoid muscles which coordinates with relaxation of the “**closing muscles**” (cricopharyngeus and inferior pharyngeal constrictor muscles) followed by propulsion of the bolus from the pharynx (throat) during the “swallowing act”. In the “resting state”, the UES is closed. UES closure is produced by contraction of the cricopharyngeus, inferior pharyngeal constrictor and cranial cervical esophagus muscles. Failure of relaxation of the cricopharyngeus muscle during a swallow produces the radiographic sign of a “**cricopharyngeal bar**” or what is more appropriately referred to clinically as a “**prominent cricopharyngeus**”. In the absence of injury, disease or pathology, the muscles constituting the UES are never contracted too tightly at rest that the UES does not open easily by a sip from a straw or a swallow of saliva. In the normal state, the UES opening and closing occurs with “little effort”. Substantial distension of the esophagus with gas or air and gastroesophageal reflux material will trigger regurgitation through the UES into the mouth.

Nerve fibers originated from the central and peripheral nervous systems and nerves traveling from the peripheral nervous system to the central nervous system finely control and coordinate each swallow. Nerve motor (contraction) input (orders) is provided by the vagus nerve branches. Injury to the vagus nerve significantly affects UES function. A tumor growing into or compressing the vagus nerve and branches will trigger dysphagia symptoms.

How wide the upper esophageal sphincter opens relates to several factors that include: 1) volume of the bolus; 2) consistency, size and shape of the bolus (physical properties); 3) rhythmic (coordinated) activity of tongue, pharyngeal constrictor, and hyoid muscles. Swallowing is a complex action that involves multiple muscles and nerve branches. Coordination of the “swallowing act” is controlled by the central and peripheral nervous systems. Injury or diseases of striated muscles or the vagus nerve can produce swallowing difficulty and delay of bolus passage.

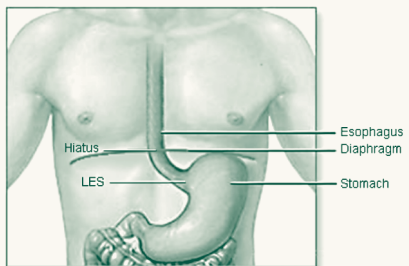
Inflammatory disorders involving muscles that affect swallowing include polymyositis and dermatomyositis. Diseases of muscle (myopathy) that may affect swallowing include drug related myopathy secondary to corticosteroid drugs, some anti-HIV (anti-retroviral) drugs and chemotherapy drugs. Congenital disorders of muscle that may affect swallowing include muscular dystrophy (generalized types) and oculopharyngeal muscular dystrophy, a specific autosomal dominant disorder observed most often in French Canadians. Neuromuscular disorders that may affect swallowing include amyotrophic lateral sclerosis (ALS or “Lou Gehrig” disease); poliomyelitis (especially bulbar type); multiple sclerosis; Parkinson disease. Disorders that involve the cortical brain grey cells such as Alzheimer disease, idiopathic dementia, infectious myelitis and encephalitis (virus and parasites), stroke may also “trip-up the swallowing act” and alter UES opening and closing.

## THE HAPPY PLATE SYNDROME

Matthew C. Hatler, B.S.

Many loving parents entice their children to finish their dinner by fostering the supreme goal at the end of the meal, a “Happy Plate!” Other children aren’t so lucky and get a stern “You finish everything on that plate or you’re not getting up from that table!” Regardless of the mechanism used to promote completion of a meal, our culture strongly suggests that if food is on your plate you should find some place for that food to fit in your stomach. Has the innocent prodding of parents’ psychologically reinforced behavior that will prove detrimental as children grow into adults? Will they continually clean their plate with no regard to the oversize portion of food that is so often presented before them? A recent study concluded that, “parents are inadvertently socializing their children to eat past their internal hunger/satiety cues” [1]. This trend demonstrates learned behavior that could continue throughout life. “Parenting style and feeding style are crucial factors in fostering healthy lifestyle and awareness of internal hunger and satiety cues”[2]. In addition to the most common reasons to abstain from overeating, such as obesity and heart disease, there are anatomical detriments to the stomach and esophagus.

When an individual overeats, the added weight of the food along with the expansion of the stomach causes undue pressure on the Lower Esophageal Sphincter (LES). The LES is a segment of esophageal muscle that seals the esophagus from the stomach and prevents the highly acidic contents of the stomach from splashing into the esophagus. Without the protective type of tissue that lines



the stomach, the esophagus lies vulnerable to acid injury. Prolonged exposure to acid in the esophagus can lead to inflammation, heartburn, strictures (narrowing) of the esophagus, dysphagia (difficulty eating), ulcers, Barrett esophagus, and esophageal cancer. Hiatal hernia is the term used to describe the abnormal protrusion of the stomach through the opening in the diaphragm, called the hiatus, through which the esophagus passes. This anatomical defect further complicates LES function as hiatal hernia has been associated with a hypotensive (low pressure) LES, causing failure of the anti-reflux barrier. The myriad of complications that may be produced by overeating can be lessened by reconditioning this harmful behavior.

Perhaps, at our dinner tables, we should explain to our children that the completion of proper food portions is really what makes a plate happy and to learn not to push themselves past their internal hunger/satiety cues. For a guide to appropriate food portions please visit [www.USDA.gov](http://www.USDA.gov) key words: Using the Food Guide Pyramid.

1. Orrell-Valente, J.K., et al., “Just three more bites”: an observational analysis of parents’ socialization of children’s eating at meal-time. *Appetite*, 2007. **48**(1): p. 37-45.
2. Golan, M. and S. Crow, *Parents are key players in the prevention and treatment of weight-related problems*. *Nutr Rev*, 2004. **62**(1): p. 39-50.

## MEDICAL MYTHS

1. **Myth: Wet hair in cold weather makes you sick.**  
**Reality:** Despite what your grandmother told you, blow-drying your hair when it’s cold out will not help ward off illness. Whether or not you catch a cold depends on your immune system and what viruses or sick people you are exposed to.
2. **Myth: Mobile phones cause brain cancer.**  
**Reality:** For radiation to cause cancer, it must break chemical bonds in the body. Only ionizing radiation can do this. Ultraviolet radiation, x-rays, and gamma rays are the culprits. Visible light and radio waves are always safe.
3. **Myth: Cracking your knuckles will cause arthritis.**  
**Reality:** There is no evidence that cracking your knuckles inflames the joints and leads to arthritis. The cracking causes

- the bones to pull apart, forming a gas bubble and breaking the adhesive seal in the joint.
4. **Myth: Eating turkey causes drowsiness.**  
**Reality:** Turkey does contain tryptophan, but it makes us sleepy only if taken on an empty stomach without protein. Sleepiness after a Thanksgiving meal is probably instead caused by carb overload (mmm... mashed potatoes!) or alcohol consumption.
5. **Myth: It’s dangerous to swim after eating.**  
**Reality:** This myth was disproved in the 60’s, but still gets trotted out. The very worst you can expect is a stitch (i.e., a short, sharp pain in the side), in which case, you should get out of the water.

(continued on page 4)

## MEDICAL MYTHS (continued)

**6. Myth: You can actually throw your back out.**

**Reality:** The fact is, you cannot throw your back out – it’s a figure of speech. However, the experience of sudden, severe back pain is no myth to the person suffering through it. And, it can certainly feel as though some major structures in the back have moved.

**7. Myth: The flu vaccine causes the flu.**

**Reality:** You cannot catch the flu from a flu vaccine. Older vaccines were less pure and sometimes caused brief reactions, such as a fever and chills. The newer flu vaccines contain only parts of the influenza virus used by the body to form an immune response.

**8. Myth: Chewing gum takes seven years to pass through your digestive system.**

**Reality:** The gum component itself is pretty indigestible, but will “pass” in a mass and will not stick your insides together.

**9. Myth: Drinking eight glasses of water a day is good for your overall health.**

**Reality:** Everyone has heard that we should drink eight glasses of water a day, but there’s no way to determine where this belief originated, not has there ever been a scientific study to support it, explains Dr. Alex Finkbeiner, Chairman of the UAMS Department of Urology. “I advise patients to simply let their thirst guide their fluid intake unless there is a specific medical reason to do differently.”

**10. Fluoride in your drinking water and dental products is bad for you.**

**Reality:** According to the American Dental Association, “Cavities used to be a fact of life, but over the past few decades, tooth decay has been reduced dramatically. The key reason: fluoride. Research has shown that fluoride reduces cavities in both children and adults. It also helps repair the early stages of tooth decay even before the decay becomes visible.”



Joy McCann Culverhouse  
**Center for Esophageal  
and Swallowing Disorders**

University of South Florida Health Sciences Center  
12901 Bruce B. Downs Blvd., MDC 72  
Tampa, FL 33612

## 9th ANNUAL

### ESOPHAGOLOGY FOR CLINICIANS POSTGRADUATE COURSE

#### Diagnosis and Therapy of Esophageal and Gastric Disorders

#### Expert Strategies and New Horizons for 2008

November 29 – December 1, 2007

Location: BoardWalk Inn, Walt Disney World  
Orlando, FL

For further information contact:  
University of South Florida  
Office of Continuing Professional Education  
P.O. Box 550610, Tampa, FL 33655-0610  
<http://www.cme.hsc.usf.edu/>  
Or Fax to: (813) 974-3217

## MEDICAL STAFF

Director .....	H. Worth Boyce, M.D. <i>Professor of Medicine and Radiology Hugh F. Culverhouse Chair in Esophagology</i>
Medical Staff .....	Milton C. Johnson, M.D. <i>Associate Professor of Medicine David S. Estores, Jr., M.D. Assistant Professor of Medicine Director, Esophageal Physiology Laboratory Joy E. Gaziano, M.A., CCC-SLP, BRS-S Instructor of Medicine Director, Section of Swallowing Rehabilitation</i>
Patient Care Coordinator .....	Janet L. Jones, B.A., CGC <i>Instructor of Medicine</i>
Assistant Patient Care Coordinators .....	Betsy J. Lamoy, R.N. Zandra V. Gadsden, LPN
Appointment Secretary .....	Nichole E. Wood
Senior Administrative Assistant/Office Manager ..	Patricia A. Crawford
Administrative Secretary .....	Natalie A. Ralyea

Center for Esophageal & Swallowing Disorders  
Phone: 813-974-3374 Fax: 813-974-7031  
Web-site: <http://swallowingcenter.health.usf.edu>

NON-Profit Organization  
U.S. Postage  
PAID  
Tampa, FL  
Permit No. 1632